

Clinical Information

DIAG Frequency Response Necessary to Reproduce ST Segment

What's Going On?

The screen of the ECG monitor displays ST segment elevation yet the diagnostic 12-lead ECG printout shows normal STs.

It may seem something is wrong, but that's not so – the product is working properly. The disparity in ECG pattern is due to the difference in frequency response between a screen display and a diagnostic recording.

It's a Matter of Frequencies

To understand the concept, consider music. The high pitched, or treble sounds are actually high frequency sound waves. The low pitched, or bass sounds are sound waves that occur at low frequencies. When you adjust the treble or bass control on the stereo receiver you cause it to filter out certain frequencies along the spectrum of sound waves to suit your personal taste. The result is that some sound frequencies are authentically reproduced, while others are damped or removed.

When the heart generates and conducts an impulse it produces an electrical signal much like music – it contains a broad spectrum of frequencies. The bandwidth or frequency response of an ECG monitor, like the stereo receiver, defines the range of frequencies that can be authentically reproduced on the display or the ECG paper. But unlike the stereo receiver, the monitor offers only one or two discrete bandwidths. In electrocardiography, the broadest bandwidth is referred to as “diagnostic frequency response” or DIAG; the range of frequencies reliably reproduces is 0.05 (low end) to 100 or 150Hz (high end). DIAG is particularly important when trying to diagnose myocardial ischemia or injury by observing for abnormalities in the ST segment and/or T-wave; these are low frequency signals. Also, pacing spikes from implanted pacemakers reside in the high end of the DIAG bandwidth.

A narrower bandwidth, called monitor frequency response, will accurately reproduce frequencies between 0.5 to 40Hz or 1.0 to 30Hz. Monitor frequency response is very useful because it filters out some of the “noise” from muscle artifact (high frequency signals). The narrower bandwidth also stabilizes the baseline which would otherwise “wander” with patient breathing or other motion (sources of low frequency signals).

Many monitor recorders have both monitor and diagnostic frequency response options available to the operator. The monitor screen of these devices, however, is limited to monitor frequency response because of limitation in display technology, and the desire for less visible noise during routine ECG monitoring. That is why the monitor screen ECG (monitor frequency response) and the recorded ECG (diagnostic frequency response) looked different.

But Wait

The original observation was that ST segment elevation was present in monitor frequency response and absent in diagnostic frequency response recording. Doesn't that seem backwards? Shouldn't monitor frequency response mask ST elevation and diagnostic frequency response pick it up?

The point is not that monitor frequency response masks ST elevation but that it does not reproduce it accurately. In some cases it may show ST elevation or depression where none exists and in others diminish the degree or entirely cancel out the baseline deviation. (See Figures 1 and 2 on back page). The recordings were from the same patient at nearly the same time: ST elevation is evident in monitor frequency response, none appears in diagnostic frequency response.

Figure 3 (on back page) is an ECG recording from another patient. The ECG trace to the left of the dashed line was recorded in monitor frequency response. The operator switched to a DIAG recording at the point of the dotted line. ST segment elevation is evident only in the DIAG portion of the recording.

This phenomenon is explained by the strength (amplitude) and direction of the QRS deflection, positive or negative, in the lead you are observing. In monitor frequency response, the beginning of the ST segment will be offset in the direction opposite the predominant QRS deflection.

In Figure 1, the QRS complex in lead I is mostly positive and the ST segment is distorted downward. The QRS complex in lead III is mostly negative and the ST segment is distorted upward. In Figure 2, the diagnostic recording gives an authentic representation of the ST segment; ST segment distortion is not present in either lead I or III.

The same phenomenon can be seen in Figure 3 but it is more subtle. The DIAG ECG recording (to the right of the dotted line) shows ST segment elevation of about 2mm in lead II. The QRS complex is positive in lead II. When the ECG is viewed in monitor frequency response (to the left of the dotted line), distortion causes the ST segment to appear at the baseline.

In summary, since monitor frequency response (1.0 to 30Hz or 0.5 to 40Hz) does not reproduce the ST segment accurately, it should not be used to determine the presence or absence of ST/T-wave changes indicative of myocardial ischemia or acute myocardial infarction. Monitor frequency response is useful in the reduction of spurious artifact from motion and vibration and is adequate when viewing the ECG for cardiac rate and rhythm. For authentic ECG recordings or diagnostic 12-lead ECGs, be sure to use the DIAG feature of the ECG device.

DIAG Frequency Response Necessary to Reproduce ST Segment

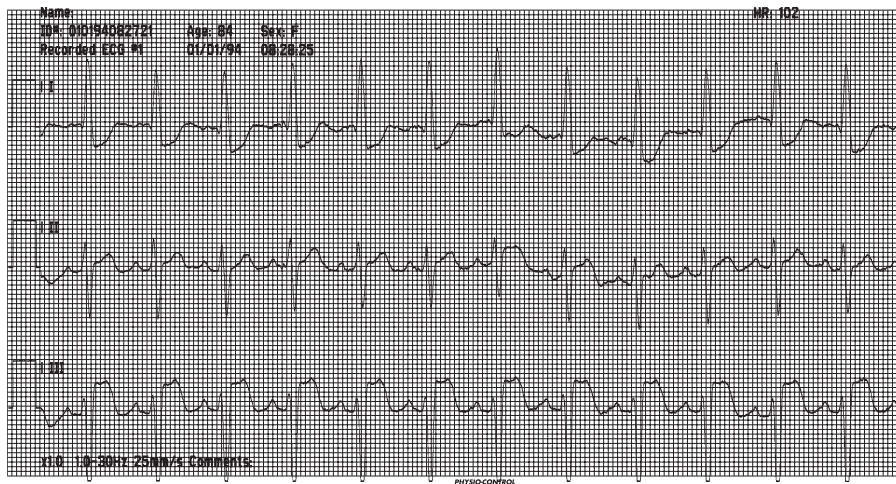


Figure 1: Monitor frequency response – ST elevation in leads II / III; ST depression in I.

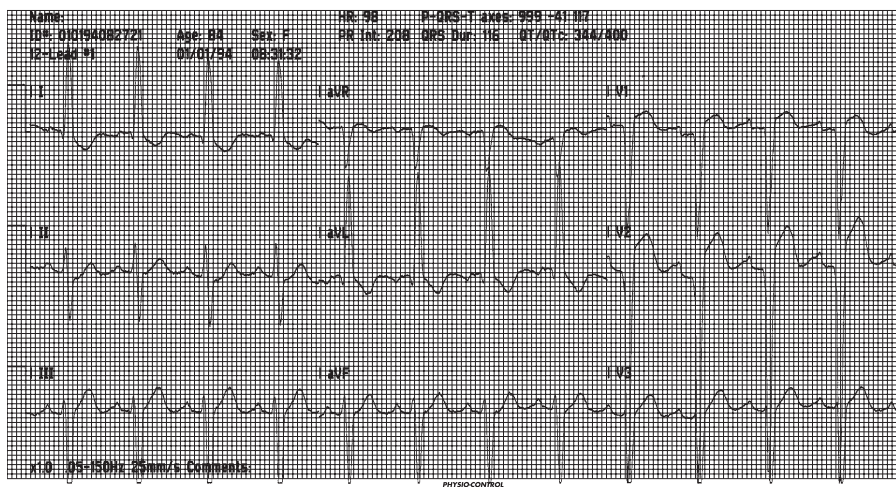


Figure 2: DIAG frequency response – no ST elevation in leads II / III; ST depression moderated in I.

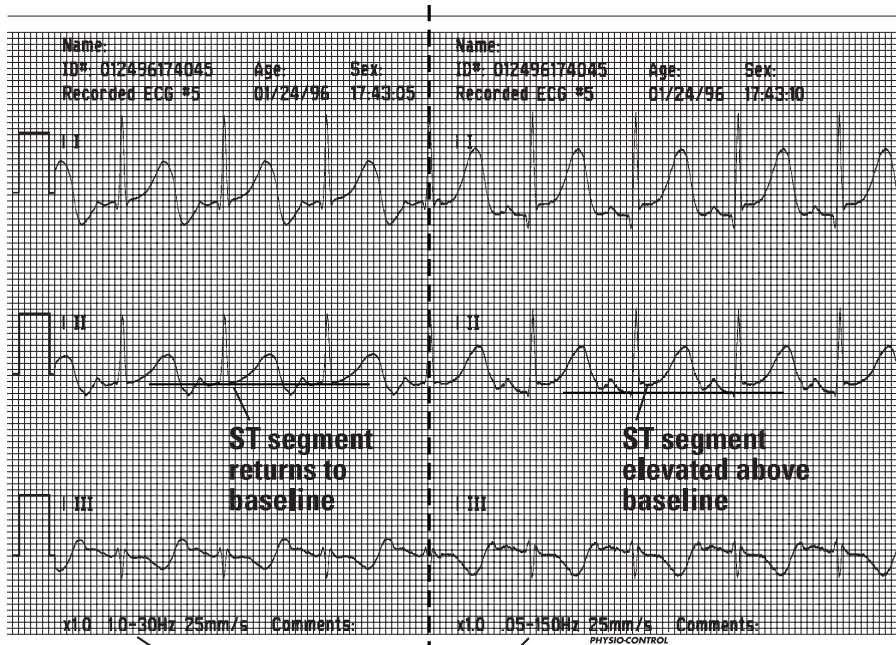


Figure 3: Monitor vs. DIAG – monitor frequency response does not accurately reproduce the ST segment.

Frequency response