

Clinical Information

Noninvasive Pacing Capture

Some of the most frequent queries addressed by the clinical specialists at Physio-Control relate to noninvasive pacing. Although the therapy has become relatively commonplace over the past 20 years, it is not so common the clinicians administer it frequently. As with anything else, the more experience one has the greater the learning and the easier the job becomes.

Interpretation of the externally paced ECG is not always simple. This article will illustrate typical paced ECGs and discuss pacing capture.

All patients who are being noninvasively paced should be continually monitored by ECG, under constant direct observation, and be frequently assessed for mechanical and electrical capture.

Electrical capture occurs when a pacing stimulus leads to depolarization of the ventricles. It is confirmed by ECG changes typical of ventricular complexes — a widening of the QRS complex and a tall, broad T wave, — displayed on the monitor (See Figures 1–3). The deflection of the captured complex may be positive or negative. Capture accompanying noninvasive pacing resembles that seen in permanent or temporary invasive pacing.

Mechanical capture is the contraction of the myocardium and is evidenced by presence of a pulse and signs of improved cardiac output. Both electrical and mechanical capture must occur to benefit the patient.

Many patients achieve capture at 50 to 90 mA, although individual thresholds vary markedly.^{1,2,3} Capture thresholds are not related to body surface area or weight,^{2,4} but recent thoracic surgery, pericardial effusion, pericardial tamponade, hypoxia, acidosis and other physiological variable may lead to higher capture thresholds.²

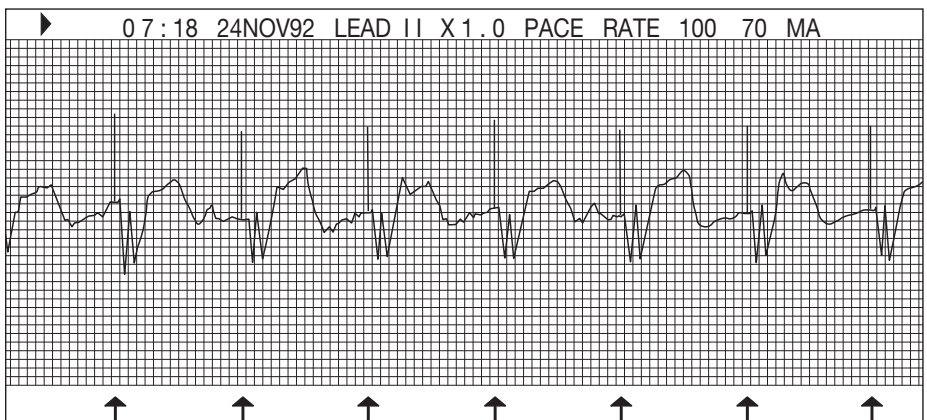


Figure 1

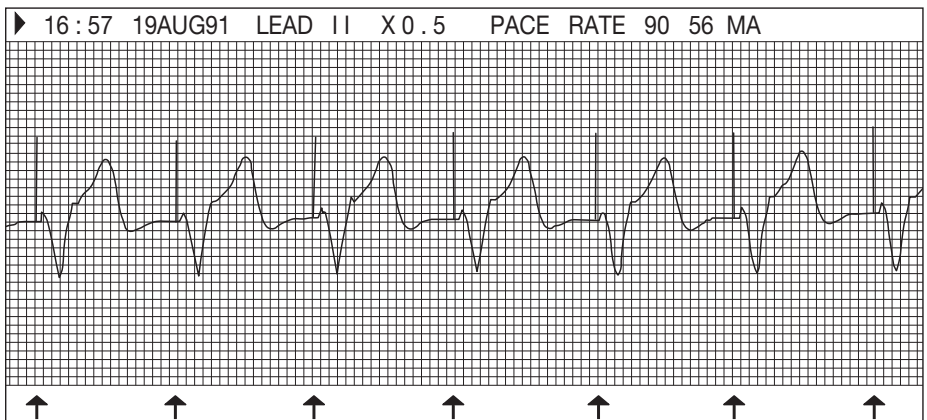


Figure 2

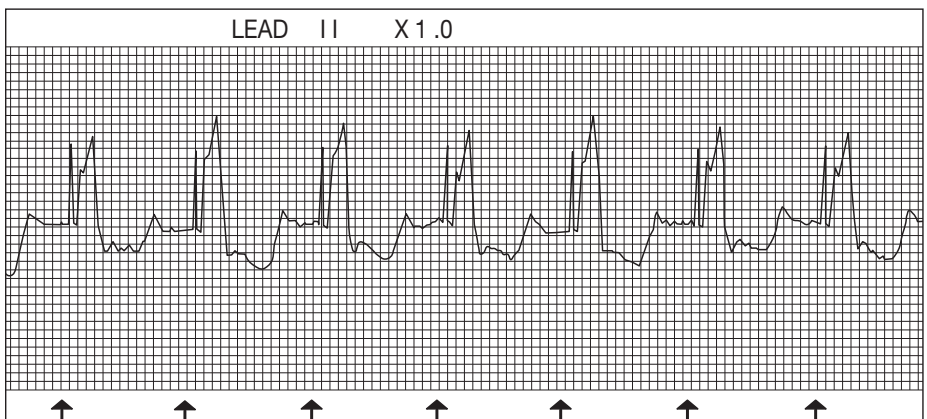


Figure 3

Noninvasive Pacing Capture

The most common error in noninvasive pacing is failure to advance the current high enough to achieve capture (See examples of intermittent capture, Figures 4–5). In conscious patients begin the procedure with pacing current set zero mA and adjust upward until capture is identified. Increase current slowly until the characteristic ECG changes occur. In unconscious patients increase current quickly to maximum and adjust downward to threshold when capture is obtained. Remember to check for signs of mechanical capture following any adjustments of pacing current.

Identifying ventricular capture takes some practice but you will quickly gain confidence by following a pacing implementation routine, examining the ECG for key characteristics of capture and observing the patient’s physical response.

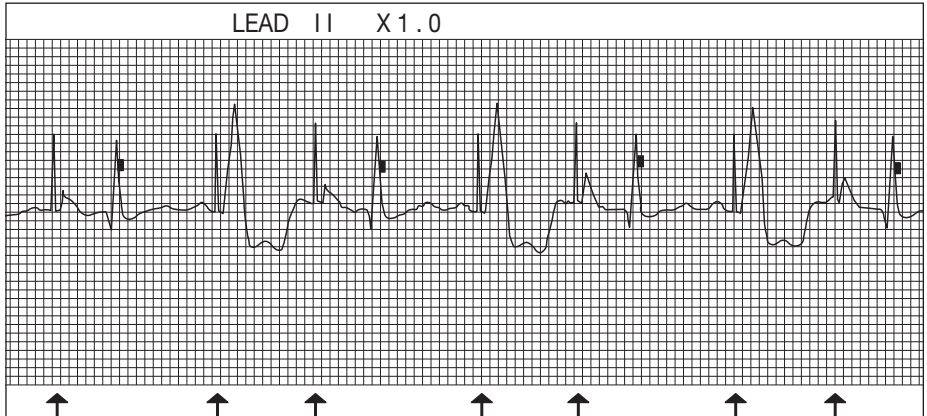


Figure 4

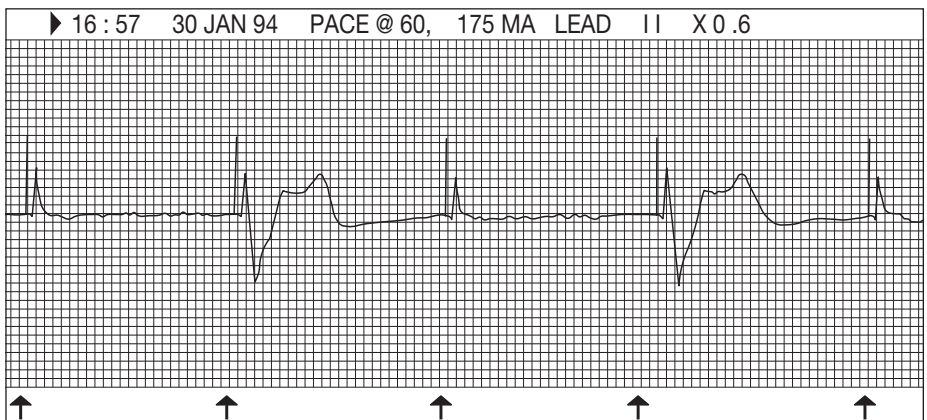


Figure 5

References

1. Madsen JK, Meibom J, Videbak R. Transcutaneous pacing: Experience with the ZOLL noninvasive temporary pacemaker. *Am Heart J.* 1988;116:7-10.
2. Kelly JS, Royster RR, Angert KC, et al. Efficacy of noninvasive transcutaneous cardiac pacing in patients undergoing cardiac surgery. *Anesthesiology.* 1989;70:747-751.
3. Sharkey SW, Chaffee V, Kapsner S. Prophylactic external pacing during cardioversion of atrial tachyarrhythmias. *Am J Cardiol.* 1985;1632-1634.
4. Beland MJ, Hesslein PS, Finlay CD, et al. Noninvasive transcutaneous cardiac pacing in children. *PACE.* 1987;10:1262-1270.



Physio-Control, Inc.
 11811 Willows Road NE
 P.O. Box 97006
 Redmond, WA 98073-9706 USA
 Tel 425 867 4000
 Toll-Free (USA Only) 800 442 1142
 Fax 425 867 4146
 www.physio-control.com