

Clinical Information

Pacing Artifact May Masquerade as Capture

Key characteristics of electrical capture in noninvasive pacing are a widening of the QRS complex and a tall broad T-wave, ECG changes typical of ventricular complexes. See Figure 1.

In some cases, artifact following the pacing current may masquerade as capture. The following discussion will help you better understand the phenomenon, differentiate between capture and artifact, remedy the problem, and anticipate additional problems associated with monitoring the externally paced patient.

The source of the problem

During external pacing, strong electrical current is transmitted through the chest to the heart. The ECG electrodes pick up the signal produced by this current and display it as artifact on a typical ECG screen. To minimize this pacing artifact on the ECG screen, monitors with integrated pacemakers intentionally blank out a brief period of ECG; the blanked period usually begins when the pace pulse is delivered and lasts 40 to 80 milliseconds, depending on the pacemaker.

A software generated pacing mark is superimposed on the ECG to signify when the current is being delivered. Although this brief loss of ECG data may not seem ideal, having an interpretable ECG signal is clearly beneficial. Without a blanking period, large artifacts and distortion of the ECG signal on the screen would make capture difficult to identify.

Despite the presence of the blanking period, occasionally some of the ECG artifact may remain and a portion may be seen immediately following the pace pulse. Although the morphology of the artifact is variable, at times it may resemble a QRS complex and can be confused with electrical capture. See Figures 2 and 3.

In extreme cases the artifact could mask an underlying rhythm such as ventricular fibrillation.

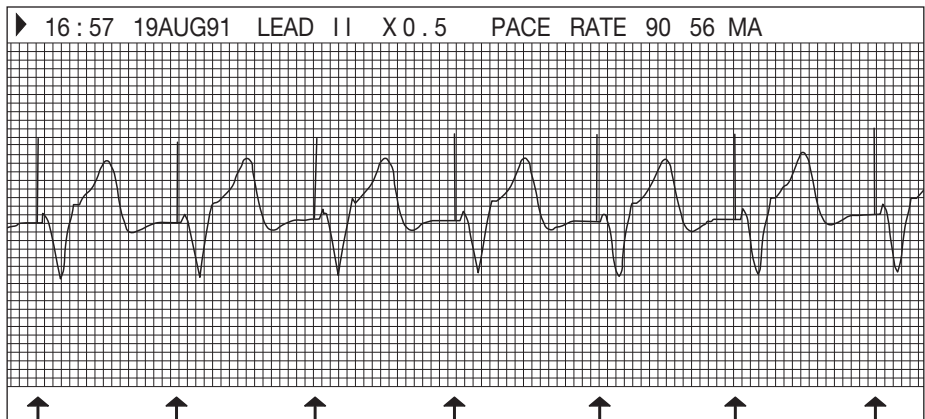


Figure 1. Typical paced ECG.

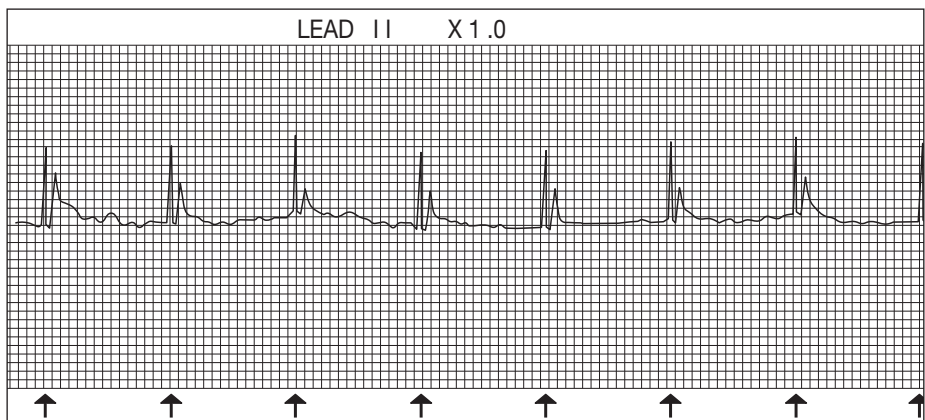


Figure 2. Example of pacing artifact which could be confused with capture.

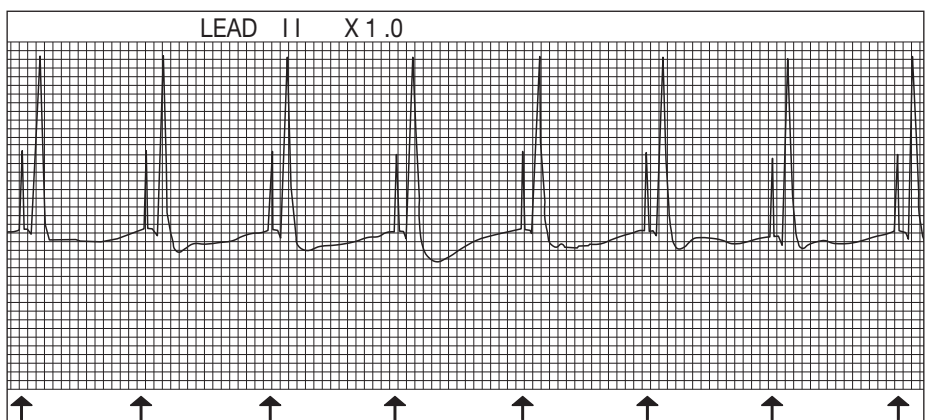


Figure 3. Example of pacing artifact which could be confused with capture.

Pacing Artifact May Masquerade as Capture

Steps to identify and minimize artifact

It is critical to distinguish between electrical capture and artifact during pacing. If in doubt, ask yourself these questions: Does the ECG trace resemble figure 1 – does it exhibit a wide QRS with a tall, broad T-wave? Can you palpate a pulse with each ECG complex? Does it more closely resemble Figures 2 and 3? If uncertain, increase the current (remember to warn the conscious patient first). Artifact will increase in size as current is increased.

If it's artifact you are dealing with, try positioning the ECG electrodes as far from the pacing electrodes as possible; this should help reduce signal distortion. If ECG signal distortion is severe it may be necessary to select another lead or reposition the ECG electrodes. Once you have done all things possible to reduce the interference, adjust the current until capture is recognized.

Monitoring the externally paced patient

Patients who are being externally paced should always be visually monitored. Heart rate detectors, if active during pacing, may not accurately count intrinsic QRS complexes or pacemaker generated complexes. The heart rate detector may incorrectly identify artifact as QRS complexes leading to false high readings. Also, intrinsic complexes which fall within the pacemaker's blanking period will not be counted by the monitor, leading to false low reading. During external pacing, the monitor's heart rate display should not be considered reliable.

Monitoring the patient involves more than watching the ECG screen and continuous patient observation. Equally important are frequent assessment of patient level of consciousness, comfort, and cardiac output. If you follow the steps above, you aren't likely to be fooled by pacing artifact masquerading as ECG capture.



Physio-Control, Inc.
11811 Willows Road NE
P. O. Box 97006
Redmond, WA 98073-9706 USA
Tel 425 867 4000
Toll-Free (USA Only) 800 442 1142
Fax 425 867 4146
www.physio-control.com