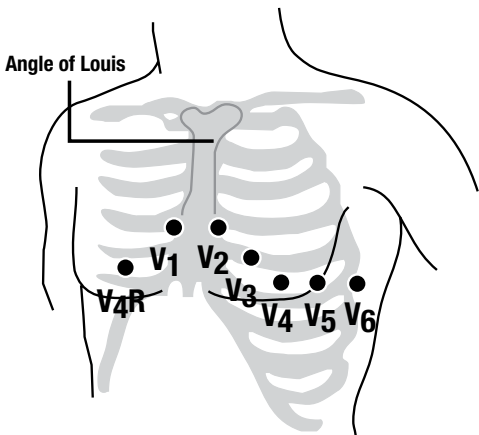


## Placement of Precordial Leads



- V1** Fourth intercostal space to the right of the sternum
- V2** Fourth intercostal space to the left of the sternum
- V3** Directly between leads V2 and V4
- V4** Fifth intercostal space at left midclavicular line
- V5** Level with lead V4 at left anterior axillary line
- V6** Level with lead V5 at left midaxillary line
- V4R** Fifth intercostal space at right midclavicular line
- V5R** Level with lead V4R at right anterior axillary line (not shown)
- V6R** Level with lead V5R at right midaxillary line (not shown)

## 12-Lead Electrocardiogram Variations in Acute Myocardial Infarction and Angina



Baseline



Ischemia — tall or inverted T wave (infarct), ST segment may be depressed (angina)



Injury — elevated ST segment, T wave may invert



Infarction (Acute) — abnormal Q wave, ST segment may be elevated and T wave may be inverted



Infarction (Age Unknown) — abnormal Q wave, ST segment and T wave returned to normal

## Location of Infarction by Leads

Inferior wall	Leads II, III and aVF
Anterior wall	Leads V3 and V4
Lateral wall	Leads I, aVL, V5 and V6
Septal wall	Leads V1 and V2
Right ventricle	Leads V4R, V5R, and V6R