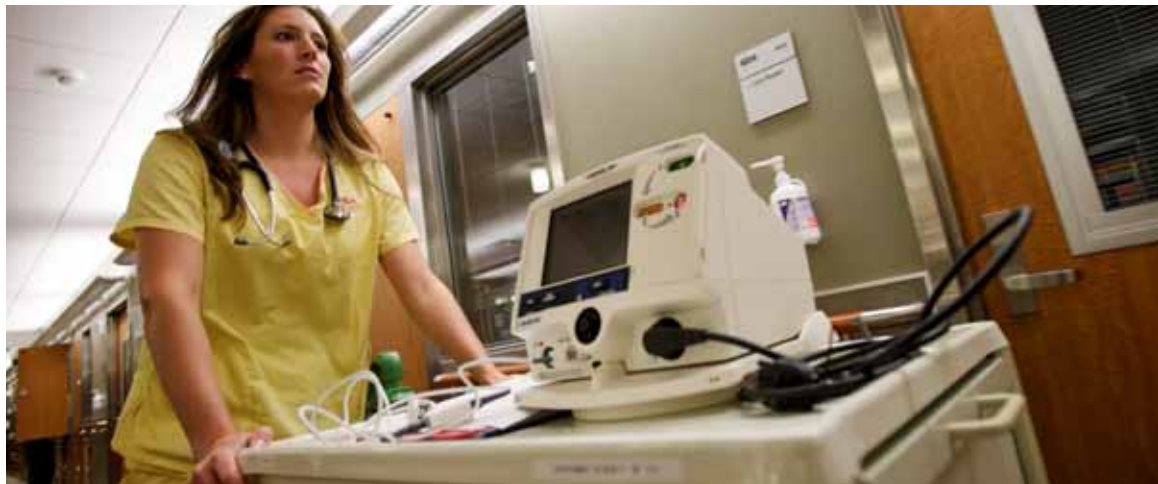

EDUCATIONAL SERIES

Noninvasive Pacing

What You Should Know



EDUCATIONAL SERIES

Noninvasive Pacing

What You Should Know

by Linda Del Monte, RN, BSN

Physio-Control, Inc.
Redmond, Washington USA

Physio-Control wishes to thank Rodney H. Falk, MD, FACC,
for his expert and constructive criticism of this material.

Contents

- 1 Introduction**
- 2 History**
- 3 Review of the Cardiac Conduction System**
 - Cardiac Conduction System
 - Failure of the Conduction System
- 4 Artificial Pacemakers**
 - Types of Artificial Pacemakers
 - Permanent Pacing
 - Temporary Pacing
 - Transvenous Pacing
 - Epicardial Pacing
 - Transesophageal Pacing
 - Percutaneous Transthoracic Pacing
- 6 Noninvasive Pacing**
 - Physiologic Effects of Noninvasive Pacing
 - Applications for Noninvasive Pacing
 - Emergency Use of Noninvasive Pacing
 - Alternative Use of Noninvasive Pacing
 - Standby Use of Noninvasive Pacing
 - Noninvasive Overdrive Pacing
- 9 Pediatric Pacing**
- 9 Demand and Non-demand Pacing Modes**
 - Demand Pacing
 - Pacemaker Timing Cycles
 - Non-demand Pacing
 - Pacing Procedure
 - Preparing the Patient and Family
- 13 ECG Electrodes**
- 14 Pacing Electrodes**
 - Anterior-Posterior Pacing Electrode Placement
 - Anterior-Lateral Pacing Electrode Placement
- 15 Selecting Mode, Rate and Current**
- 15 Assessing for Capture**
- 18 ECG Signal Distortion During Pacing**
- 19 Mechanical Capture**
- 20 Troubleshooting**
 - Discomfort
 - Failure to Capture
 - Noisy ECG Signal
 - Undersensing
 - Oversensing
- 22 Safety Precautions**
- 23 Summary**
- 24 Noninvasive Pacing Procedure**
- 25 Troubleshooting Guideline**
- 26 Nursing Care Plan**
- 27 Frequently Asked Questions**
- 29 References**
- 30 Glossary**

Introduction

This booklet is a concise reference for noninvasive pacing. Over the course of this booklet important concepts in noninvasive pacing will be shared including a review of the conduction system, types of pacemakers, applications for noninvasive pacing, pacing modes, pacemaker timing cycles, the pacing procedure, troubleshooting guidelines and nursing care plan.

This booklet is not intended to replace the operating instructions, local protocols or institutional guidelines.

History

Cardiac pacing has been studied by researchers and clinicians since the late 1800s.¹ In 1952, utilizing somewhat rudimentary technology, noninvasive pacing was successfully used for the treatment of Stokes-Adams attacks associated with heart block.² The theory behind noninvasive pacing was if a strong electrical current were applied to the chest, a small portion would reach the heart stimulating it to depolarize and contract. Later, noninvasive pacing was used with considerable success for ventricular standstill or profound bradycardia associated with reflex vagal stimulation, drug toxicity and cardiac arrest.^{2,3,4}

Noninvasive pacing, while effective, was not without problems. Skeletal muscle and cutaneous nerve stimulation was common and painful. Small electrodes (3 cm diameter) resulted in high current density which was associated with painful cutaneous nerve stimulation and superficial skin lacerations under the electrodes after more than one day of pacing.⁴ Interpretation of capture on the electrocardiogram was difficult due to large artifacts associated with the pacing stimulus and patient movement. If electrodes were placed too near the diaphragm, the electrical stimulation caused apnea thought to be from interference with diaphragmatic movement.⁴ Also, noninvasive pacing could not be used as a permanent treatment for conduction problems. For these reasons, in the late 1950s, the development of transvenous endocardial pacing largely replaced noninvasive pacing.

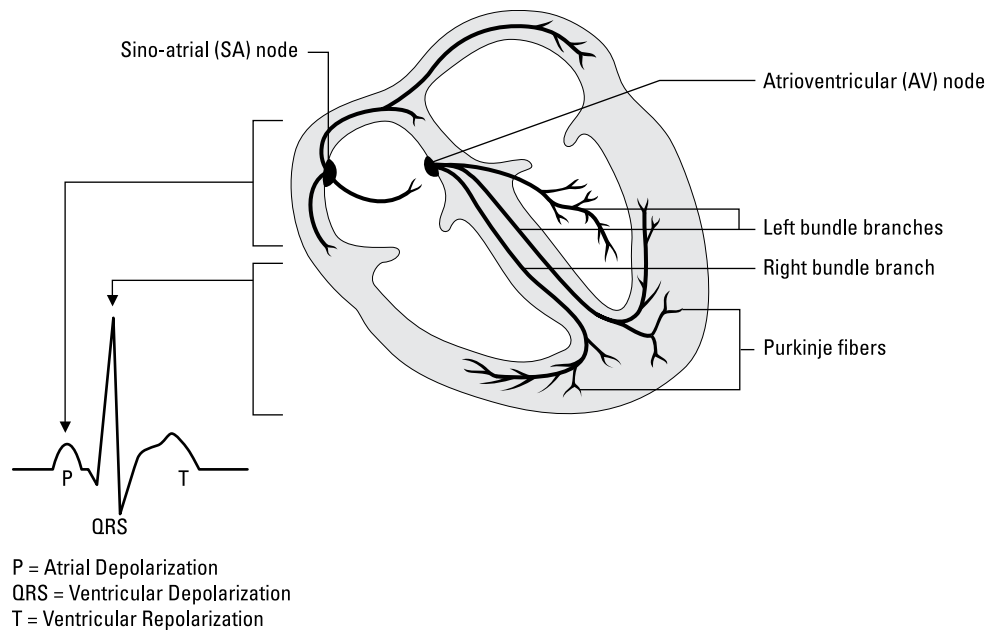
In the 1980s, due to advances in technology, noninvasive pacing reemerged as an emergency therapy for symptomatic bradycardia and asystole. Advances included the development of large adhesive electrodes and ECG filtering which overcame the early problems of extreme discomfort and ECG capture interpretation. In addition, laboratory research identified the importance of a prolonged pulse duration for reducing discomfort and lowering capture thresholds.⁵

Investigators, using a theoretical model, concluded that pace stimulus durations of 10 milliseconds (ms) or more produced less discomfort than shorter duration pulses.⁶ Researchers also determined that there was no difference in discomfort level and pacing thresholds with pulse widths of 20 to 40 ms.⁷

Noninvasive pacing has come full circle since the 1950s and is today the most common form of emergency pacing.

Review of the Cardiac Conduction System

The conduction system is a network of specialized tissue in the heart. Its function is to generate electrical impulses and transmit them throughout the heart. The impulses stimulate the muscle cells causing them to depolarize. Depolarization is normally followed by myocardial contraction and a pulse.



Normal conduction pathway in the heart

Cardiac Conduction System

The heart's natural pacemaker is the sino-atrial (SA) node, located in the right atrium. The SA node initiates an impulse 60 to 100 times per minute. The impulse spreads throughout the atria and results in depolarization and contraction of the atria, ejecting blood into the ventricles. From the atria, the impulse travels to the atrioventricular (AV) node, where conduction slows to allow time for blood to flow from the atria into the ventricles. The impulse continues through the bundle of His, down the right and left bundle branches, and throughout the ventricles via the Purkinje fibers. This causes ventricular depolarization followed by contraction which creates a pulse.

Electrical activity of the atria is seen as the P wave on an electrocardiogram (ECG). Conduction delay between atrial and ventricular depolarization is seen on the ECG as the PR interval. Ventricular depolarization is represented by the QRS complex. The T wave represents repolarization of the ventricles.

After muscle fibers contract, they cannot respond to an electrical impulse for a short period of time known as the refractory period. During this time, the muscle fibers repolarize and return to a resting state. The ventricular refractory period begins with the onset of the QRS complex and is complete near the end of the T wave.

The conduction system tissue and many of the myocardial cells themselves have the ability to initiate an electrical impulse, a property known as automaticity. Each area in the conduction system has an inherent rate of impulse generation. Impulse generation occurs 60 to 100 times per minute in the sinus node, 40 to 60 times per minute in the AV node and 20 to 40 times per minute in the ventricular conduction system.

Failure of the Conduction System

Any portion of the specialized conduction tissue in the heart may fail. If the SA node fails to generate an impulse, conduction tissue farther down the line will initiate one. Generally speaking, the farther down the conduction system the failure occurs, the slower the heart rate.

There are several reasons why the conduction system may fail including coronary artery disease, acute myocardial infarction, drug or toxin overdose, fibrosis of the conduction system, acute renal failure, trauma or hypoxia. Conduction of impulses may not occur in areas of damaged conductive tissue and lower pacemakers may need to take over. This may result in a slow heart rate (bradycardia) or in extreme cases cardiac standstill (asystole).

Artificial Pacemakers

When the heart's intrinsic pacemakers fail, an electronic device called a pacemaker may be used to initiate electrical impulses.



An artificial pacemaker is a device that delivers an electrical stimulus from a pulse generator via a lead wire system to the heart muscle causing depolarization of the myocardium. This is seen as “electrical capture” on the ECG display. Normally, depolarization results in contraction of the myocardium. Myocardial contraction following this depolarization is termed “mechanical capture” and is confirmed by palpating a pulse. Both electrical and mechanical capture must occur to benefit the patient.

Types of Artificial Pacemakers

There are two general categories of artificial pacemakers, permanent and temporary.

Permanent Pacing

Permanent implantable pacemakers were introduced in 1960. They are implanted into the body because of a permanent conduction problem.⁸ One or two pacing lead wires are placed via the venous system into the right ventricle or atrium. Epicardial wires may also be used for permanent pacing. The lead wires are connected to a pulse generator which is implanted subcutaneously and the pacemaker is programmed for the individual patient's needs. Pacemakers may pace a single chamber activating the atria or ventricle or may be “dual chamber” activating the atria and ventricles in a sequential manner known as AV synchrony.⁹ Permanent pacing has provided a safe, long-term method for controlling selected intermittent or sustained bradycardias and for prolonging survival.¹⁰

Temporary Pacing

Temporary pacemakers are used in emergency situations for transient conduction disturbances or prophylactically for anticipated dysrhythmias. They are typically used for less than three days.¹¹ Temporary pacemakers may be invasive or noninvasive. Temporary pacemakers include transvenous, epicardial, transesophageal, transthoracic or noninvasive.

Transvenous Pacing

Transvenous pacing, developed in 1959, is the most common method of temporary pacing. A physician inserts a pacing catheter into the right ventricle via the venous system. In select cases temporary atrial pacing may be performed. The catheter is connected to an external pulse generator.¹²

This method is generally reliable once instituted and is typically well tolerated by the patient. Although transvenous pacing has been widely used since its inception, the transvenous method has several disadvantages. A skilled physician must insert the pacing catheter, usually assisted by nursing personnel. Insertion can be time consuming and sometimes requires fluoroscopy. Thus, transvenous pacing is less practical in the out-of-hospital environment. Although current insertion techniques limit the risks associated with transvenous pacing, complications such as infection, bleeding, pulmonary embolism, pneumothorax, cardiac tamponade and ventricular tachycardia can occur.¹³ Finally, transvenous pacing is expensive. Costs include the pacing catheter and supplies, physician's time and occasionally fluoroscopy. If pacing intervention is not immediately indicated but may be in the near future (standby pacing), noninvasive pacing may be more cost-effective.¹⁴

Epicardial Pacing

The most common use of epicardial pacing is for the cardiac surgery patient. Temporary wires are sutured loosely to the outermost layer of the heart and then exposed through the skin. These lead wires are then connected to an external pulse generator similar to transvenous pacing.

Epicardial pacing is usually well tolerated by patients. It can be reliably used for maintaining adequate cardiac output as well as suppressing and assisting in the diagnosis of dysrhythmias. Emergency use of epicardial pacing has limited use in patients undergoing open thoracotomy for penetrating trauma.¹⁶ The main disadvantage of epicardial pacing is that an open thoracotomy is required and therefore its use is confined to patients undergoing open chest surgery. Complications of epicardial pacing include pericardial tamponade during wire removal, wire fracture or dislodgment, scar tissue and infection.¹⁵

Transesophageal Pacing

Transesophageal pacing was developed in 1969 and is most commonly used for treatment of sinus bradycardia, supraventricular tachycardia or for diagnostic studies. An electrode is placed in the esophagus through the nose or by a pill-electrode which is swallowed. The electrode is connected via a wire to an external pulse generator. The electrode is advanced to approximately the mid-esophageal level and atrial pacing is attempted at this point. If unsuccessful, then the position of the electrode is adjusted until pacing capture is obtained.

The electrode is relatively easy to insert and there are few reported complications. The distance between the electrode and the ventricular wall makes ventricular capture unreliable and uncomfortable. Therefore, transesophageal pacing is commonly used only for atrial pacing.¹²

Percutaneous Transthoracic Pacing

Percutaneous transthoracic pacing involves a physician inserting a pacing wire or catheter into the right ventricle via a percutaneous needle through the anterior chest. An external pulse generator sends the electrical impulses through the catheter to depolarize the right ventricle. Percutaneous transthoracic pacing has been shown to be of limited value because of frequent complications and low success rates.^{12,17} For these reasons, it is rarely used today.

Noninvasive Pacing

Noninvasive pacing is primarily used for emergency treatment of symptomatic bradycardia. Electrical current is passed from an external pulse generator via a conducting cable and externally applied, self-adhesive electrodes through the chest wall and heart. Other terms for noninvasive pacing are transcutaneous, transthoracic or transthoracic pacing.

Noninvasive pacing is comparatively easy to perform and requires minimal training. It can be initiated by nurses, paramedics, physicians and other emergency cardiac care providers. Requiring very little set-up time, it generally does not include any of the complications associated with invasive techniques. It is the least expensive pacing approach and may be used for standby pacing, reducing the need for prophylactic placement of a transvenous catheter. It is especially useful for patients at high risk for infection or bleeding. The major disadvantage of noninvasive pacing is discomfort. Current is applied across the chest which results in cutaneous nerve stimulation as well as skeletal muscle stimulation.



Physiologic Effects of Noninvasive Pacing

Several studies have been performed to evaluate the hemodynamic response to noninvasive pacing. Investigators have measured mean arterial pressure (MAP), cardiac output (CO) and systemic vascular resistance in dogs during transvenous, transthoracic and noninvasive pacing. Mean arterial pressure and cardiac output increased with all three pacing techniques, while systemic vascular resistance decreased. Niemann observed a significantly higher increase in MAP and CO with noninvasive pacing, while Syverud noted a slightly higher MAP with transvenous pacing.^{18,19}

Feldman studied the hemodynamic response to noninvasive pacing in anginal patients during cardiac catheterization. He found that noninvasive pacing increased heart rate, mean oxygen consumption and arteriovenous oxygen

difference when the pulse rate was increased to within 85% of age-predicted maximal heart rate.²⁰ These effects could be undesirable in some patients with acute myocardial infarction. Before a conclusion can be drawn, further research is needed.

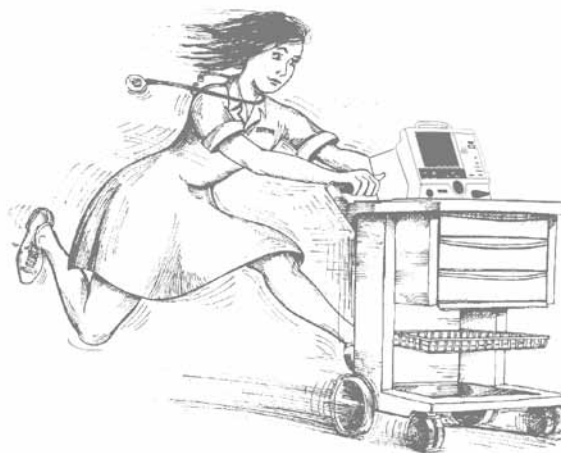Several investigators have done studies to determine which cardiac chambers are stimulated during noninvasive pacing. Animal studies demonstrate simultaneous activation of both the atria and the ventricles.⁵ In humans, the ventricles are directly stimulated and frequently the atria are activated by retrograde (in a backward direction) conduction.²¹ Atrioventricular (AV) synchrony is not present. Without atrial contribution, there is a subsequent decline (about 20%) in cardiac output.²² Another area of research interest is the effect of noninvasive pacing on the myocardium. In animals, minor pathological changes were noted without clinically detectable alterations in cardiovascular status.^{23,24} Two studies looked at CKMB levels before and after noninvasive pacing. CKMB is an enzyme found in myocardial cells; when the cells are injured, as in a myocardial infarction, CKMB is released into the bloodstream and can be measured to indicate myocardial damage. One investigator measured CKMB fractions in dogs and found no rise in the levels after noninvasive pacing.²³ More recently, another investigator measured CKMB levels and evaluated left ventricular function in healthy human subjects.²⁵ He found no significant changes after thirty minutes of pacing.

Applications for Noninvasive Pacing

Noninvasive pacing has many uses in the hospital as well as the out-of-hospital setting. In both settings, noninvasive pacing initiated at the onset of the rhythm disturbance may result in increased patient survival rates.²⁶ Applications for noninvasive pacing can be grouped into three broad categories: emergency use, as an alternative to invasive pacing, and for standby use. Noninvasive pacing is occasionally used in overdrive and pediatric pacing.

Emergency Use of Noninvasive Pacing

In emergency situations noninvasive pacing can serve as a therapeutic bridge. It can be rapidly initiated to stabilize the patient's rhythm and allow time to plan further care.



Noninvasive pacing is often beneficial for patients with hemodynamically unstable bradycardia, especially if the patient is unresponsive to pharmacologic intervention with atropine sulfate. If there are delays in intravenous access or atropine is not reversing the bradycardia, pacing administration should not be delayed. In out-of-hospital studies pacing was most effective when patients with symptomatic bradycardias still had a palpable pulse when paramedics arrived on scene and began treatment.^{28,29}

Pacing can be considered for patients in cardiac arrest due to drug overdose or patients with pulseless electrical activity due to acidosis or electrolyte abnormalities. Pacing patients as soon as possible while correcting the acidosis or abnormalities may stimulate effective myocardial contractions until the conduction system can recover. Poor survival rates for out-of-hospital patients with asystole were postulated to be related in part to long patient downtimes prior to the initiation of pacing and the late application of pacing in treatment protocols.³⁰ Investigators studied both time factors and found that asystole is most often an indicator of a dead heart, rather than a rhythm which responds to treatment.³¹ Anecdotal positive outcomes for pacing asystole have been documented;^{14,32} however, most studies of asystolic patients demonstrate no improvement in survival with pacing.^{28,30,31,33}

Alternative Use of Noninvasive Pacing

Noninvasive pacing can be used when invasive pacing is undesirable, e.g., in patients with the potential for excessive bleeding, such as those receiving thrombolytic therapy, where there is increased potential for infection, as in patients with a suppressed immune system or systemic infections, or where placement of a temporary wire might be difficult, such as in patients with tricuspid valve prosthesis.

Standby Use of Noninvasive Pacing

Noninvasive pacing should be used on standby in situations when the patient is clinically stable yet may quickly decompensate or become unstable.²⁷ Patients who may benefit from standby pacing include: cardiac patients undergoing surgery, patients with acute MI and signs of early heart block, patients needing surgery for permanent pacemaker implantation, pulse generator change, or lead wire replacement, patients undergoing cardiac catheterization or angioplasty, and those with risk of developing post-cardioversion bradycardias.

Noninvasive Overdrive Pacing

While not frequently used, another potential application for noninvasive pacing is the termination of supraventricular or ventricular tachycardias by overdrive pacing.^{34,35,36} Pacing the heart at a rate faster than the tachycardia may interrupt the tachycardia and allow the SA node to regain control of the heart.

Fast rate pacing has the serious disadvantage of potentially accelerating the tachycardia or triggering ventricular fibrillation.^{34,35} Therefore, use of this technique is limited to experienced clinicians in a controlled setting, usually an electrophysiology lab. Most noninvasive pacemakers will not accommodate the rates needed for overdrive pacing or very rapid tachycardias. Typical maximum noninvasive pacemaker rates are 170 to 180 pulses per minute.

For supraventricular and ventricular tachycardias, drug therapy remains the standard treatment for stable patients and electrical cardioversion is preferred for unstable patients.²⁷

Pediatric Pacing

Noninvasive pacing as well as transesophageal pacing has been recommended for pediatric patients with bradycardia with severe cardio-pulmonary compromise.³⁷ Oxygenation, ventilation and drug therapy remain priorities in treatment. Although pediatric populations are not at risk for bradycardia from coronary artery disease, they may have bradycardia from drug or toxin ingestions.³⁸ Congenital or surgically acquired AV block may also necessitate pacing. Standby noninvasive pacing is used during permanent pacemaker generator repair or replacement.³⁹

Most adult pacing electrodes are suitable for pediatric patients weighing approximately 33 lbs (15kg) or greater. Pediatric pacing electrodes should be used on patients under 33 lbs.⁴⁰ Electrode placement landmarks are the same for pediatric and adult patients, although placement may be more challenging in infants and small children due to limited area on the torso. Capture thresholds for pediatric patients are comparable to adult capture thresholds.⁴⁰

Complications associated with pediatric pacing include skin burns, respiratory distress, and severe skeletal muscle contractions. Ventilatory support should be available. Skin assessment should be done frequently (at least every 30 minutes). Analgesia or sedation should always be used in the conscious patient. Neuromuscular blockers may be considered in an intubated patient.³⁹

Demand and Non-Demand Pacing Modes

Noninvasive pacemakers may offer two pacing modes: demand and non-demand (sometimes referred to as asynchronous or fixed rate).

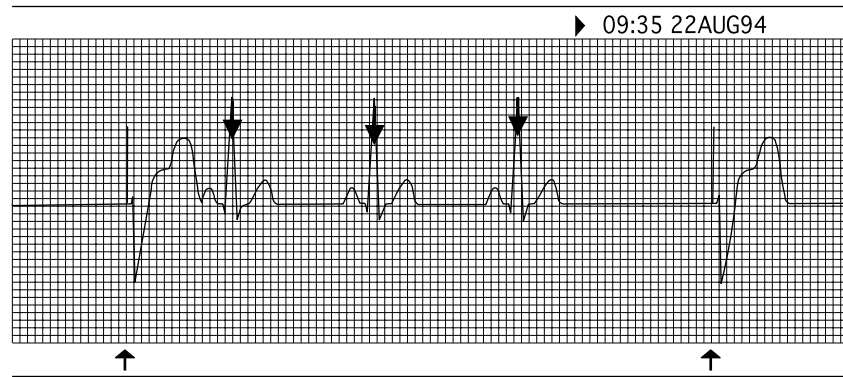
Demand Pacing

In the demand mode, the pacemaker delivers an impulse only when it is needed. The demand pacemaker searches for intrinsic cardiac activity. If it does not detect or sense a beat within a designated interval it will deliver a pace impulse. When it detects an intrinsic beat it will reset its timer and continue the search for intrinsic cardiac activity.

Some devices mark intrinsic electrical activity by a square (■) or triangle (▼) on the QRS complex (sense mark). Adjusting the pacemaker's ECG size control may be needed for proper sensing. Sensing should be verified at the initiation of pacing and at frequent intervals during demand pacing.

Pace markers or "spikes" (|) appear on the monitor and are software generated marks (nonphysiologic upward or downward deflections on the ECG monitor or recording paper) which represent the time of current delivery. Some devices may also mark pace pulse timing by arrows (↑) at the lower margin of the ECG strip.

Demand pacing is the preferred method of pacing. This mode allows the patient's intrinsic rhythm to take over when it exceeds the set pacing rate.



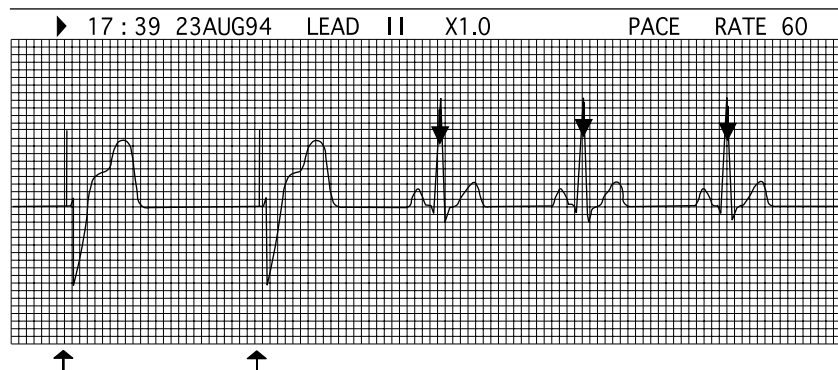
Demand pacing delivers impulse only when needed. Pacemaker is inhibited when the patient's intrinsic rate is higher than set pace rate.

Pacemaker Timing Cycles

The pace interval can be examined in order to verify the pacemaker is delivering current at the desired rate.

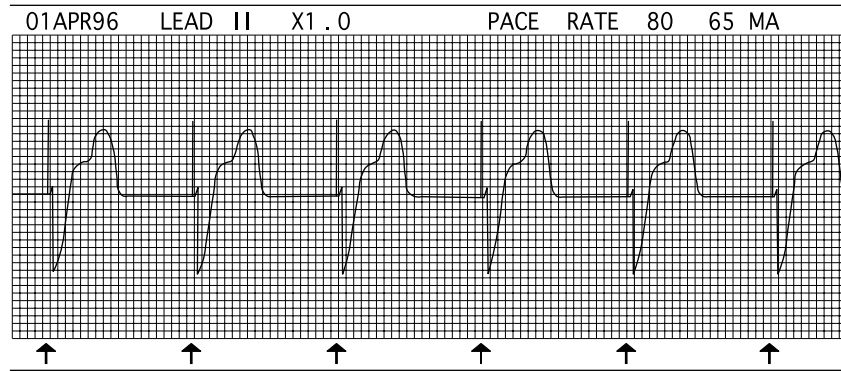
The pacing rate is measured in pulses per minute (PPM). The time period between each pulse is called a pace interval. Pace intervals are measured in milliseconds (ms). To determine the pace interval divide 60,000 ms (which equals 60 seconds or 1 minute) by the pace rate.

For example, to determine the pace interval at a pace rate of 60 PPM divide 60,000 ms by the pace rate (60 PPM). The pace interval is 1000 ms (one second). Therefore a pace pulse should be expected every 1000 milliseconds unless intrinsic activity is sensed. Hint: The smallest box on ECG paper equals 40 ms. One large square equals 200 ms.



Pace rate is 60 PPM. Pace interval equals 1000 ms (one second).

If the pace rate is 80 PPM divide 60,000 ms by the pace rate (80 PPM). The pace interval is 750 milliseconds; therefore, a pace pulse should be expected every 750 milliseconds unless intrinsic activity is sensed.



Pace rate is 80 PPM. Pace interval equals 750 ms (.75 second).

Demand pacing allows intrinsic complexes, if properly sensed, to regulate delivery of the pace stimulus and maintain the set pace rate. If intrinsic activity is identified before the pace interval expires, the QRS complex will be sensed and the timing cycle will begin again from the detected point.

In the demand mode, noninvasive pacemakers have a brief period of time after delivery of the pace pulse called the refractory period during which the pacemaker will not sense. The refractory period allows pacemaker generated QRS complexes to be ignored and the set pace rate to be maintained. Without a refractory period, the pacemaker would sense its own generated QRS complexes or T waves, and would reset the timer from this point. The next pace pulse would be delayed and the pacemaker would not maintain the set pace rate.

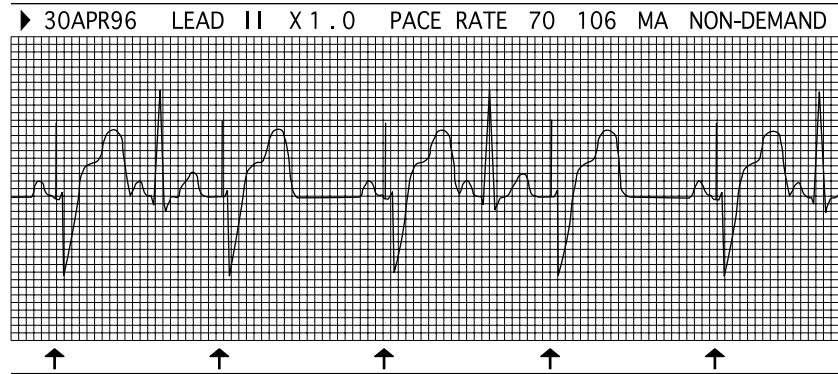
The duration of the refractory period is usually variable and ranges from approximately 200–350 ms. As the pacing rate increases, the refractory period shortens.

If an intrinsic complex falls within the pacemaker's refractory period, it will not be sensed and the pace interval will not be reset.

Non-Demand Pacing

The non-demand pace mode delivers electrical stimuli at the selected pace rate regardless of the patient's intrinsic cardiac activity. This mode of pacing may be used when inhibition of a pacemaker occurs due to sensing of signals other than R waves, such as muscle artifact, or P or T waves (oversensing) and other troubleshooting measures are unsuccessful.

During non-demand pacing, competition between the pace stimuli and the patient's intrinsic beats may occur. Although the pace stimulus may fall on a T wave, it appears the risk of inducing ventricular tachycardia or ventricular fibrillation is more a theoretical than an actual risk. In canine studies, the amount of energy needed to induce ventricular fibrillation is approximately 12 times the amount needed to pace the heart.⁴¹ Patients with cardiac ischemia are at risk for developing ventricular dysrhythmias and a defibrillator should always be available during noninvasive pacing, regardless of which pacing mode is selected.

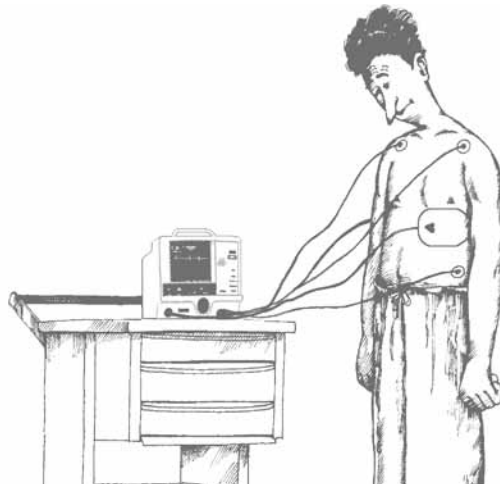


Non-demand pacing: Pacemaker delivers current at selected rate and ignores intrinsic beats.

Pacing Procedure

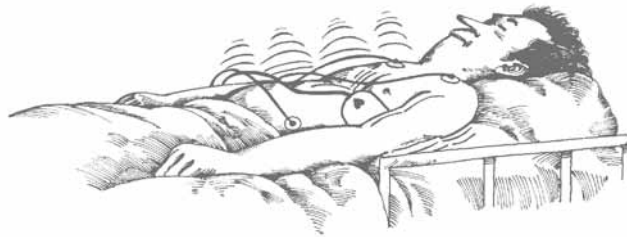
Overall, the pacing system is simple. An ECG monitor, ECG electrodes and cable are needed to display the ECG and monitor the response to pacing therapy. A pacing cable and pacing electrodes are used to deliver pacing current from the pulse generator to the patient.

The pacing procedure includes several important steps such as preparing the patient and family, placing ECG and pacing electrodes, selecting the pacing mode, rate and current, as well as assessing for capture.



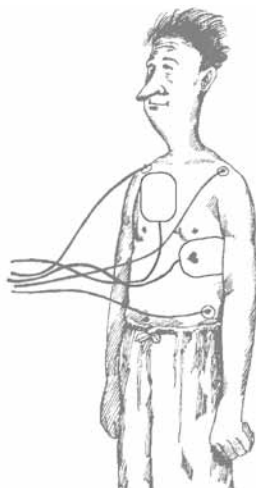
Preparing the Patient and Family

A general explanation of the procedure, and discussion of the discomfort and the skeletal muscle contractions associated with pacing will help prepare the patient and family. The level of discomfort varies according to several factors: the patient's anxiety level and tolerance of pain, the polarity of the electrodes, and the level of current needed for capture. Discomfort associated with pacing has two components: cutaneous nerve stimulation which results in tingling, stinging, pinching, or burning sensations and skeletal muscle contraction which may be felt as tapping, twitching or thudding sensations. Most patients will better tolerate the procedure with sedation or analgesia.



ECG Electrodes

ECG signal quality is important during demand pacing for accurate sensing as well as interpretation of pacing results. Using fresh, high quality ECG electrodes and proper skin preparation under the ECG electrodes is key. Poor ECG signal quality during pacing may be avoided or reduced if the skin is clean and dry. Excessive chest hair should be removed. Briskly rubbing the skin before placing the ECG electrodes may improve the monitor signal quality. It is important to place the ECG electrodes as far away from the pacing electrodes as possible in order to obtain a clear ECG signal. This will minimize the corruption of the ECG signal by the pacing current.



Placement of ECG electrodes during pacing.

Pacing Electrodes

Several electrode choices are available for monitoring, defibrillation and noninvasive pacing. Pacing electrodes may be multi-functional (monitoring, defibrillation and pacing) or single function (pacing only).

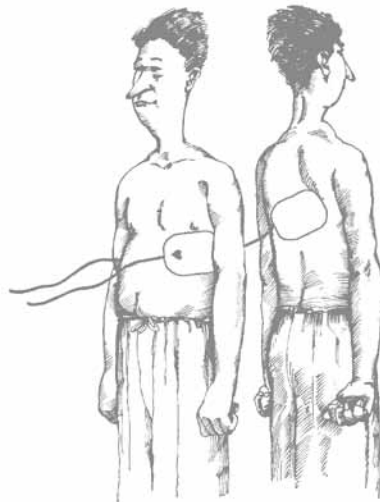
During demand pacing ECG monitoring must be done through ECG electrodes regardless of the type of pacing electrodes used. Although multi-function electrodes are capable of performing all three functions separately, available technology does not permit them to pace and monitor simultaneously. The repetitive pacing current, large in comparison to the ECG signal being monitored, would disrupt the ECG display with every pacing stimulus delivered. This would make monitoring through the same set of electrodes while pacing current is being delivered, impossible.

Skin preparation under the pacing electrodes is important although it is often done hastily due to the emergent nature of the procedure. If chest hair under the pacing electrodes is excessive, it should be removed. Failure to do so may result in higher patient impedance and in extreme cases, “pacing leads off” alarms. In conscious patients, clip rather than shave the hair as tiny nicks in the skin from shaving may greatly increase patient discomfort. Ideally, the skin under the pacing electrode should be cleaned with soap and water, dried, and then gently abraded. Alcohol, benzoin or antiperspirant should not be used to prep the skin. The pacing electrodes should then be placed securely on the clean, dry skin.

Manufacturer recommendations for placement of pacing electrodes and cables should be followed. Do not reverse the recommended placement for the pacing electrodes and pacing cable. If the electrodes or cables are reversed, failure to capture or extremely high capture thresholds may result.⁴²

Anterior-Posterior Pacing Electrode Placement

The most common pacing electrode placement is anterior-posterior. If using “pace only” electrodes the anterior-posterior placement does not interfere with placement of defibrillation paddles.



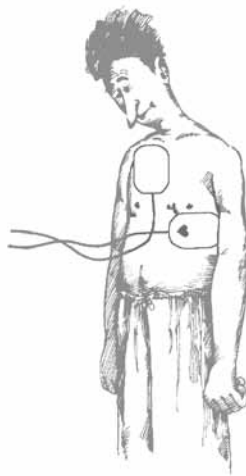
Anterior/posterior pacing electrode placement.

The anterior electrode is placed on the left anterior chest, halfway between the xiphoid process and left nipple at the apex of the heart. The upper edge of the electrode should be below the nipple. This corresponds to the V2–V3 ECG electrode position. If possible, avoid placement over the nipple, diaphragm or sternum. The posterior electrode is placed on the left posterior chest beneath the scapula and lateral to the spine at the heart level. Avoid placement of the electrode over bony prominences of the spine or scapula.

Anterior-Lateral Pacing Electrode Placement

The anterior-lateral (sternum apex or anterior-apex) placement may also be used for pacing. This placement allows easy access to the patient's chest and is usually more convenient in cardiac arrest. If using "pace only" electrodes, the anterior-lateral placement may interfere with placement of defibrillation paddles. Capture thresholds and capture rates are similar for anterior-lateral and anterior-posterior placements.⁴²

The lateral (apex) electrode is placed on the left anterior torso, just lateral to the left nipple in the midaxillary line. This corresponds to the V6 electrode position. The anterior electrode is placed in the right subclavicular area lateral to the sternum.



Anterior/lateral pacing electrode placement.

Selecting Mode, Rate and Current

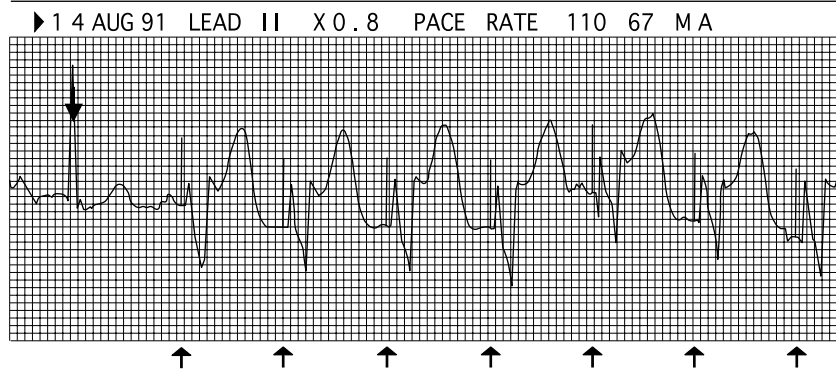
Pacing current should remain at zero milliamperes (mA) until the pacing mode has been selected and proper sensing (if demand pacing is selected) has been verified. Current may then be adjusted upward until capture is identified. In conscious patients increase the current slowly while assessing for capture. For patients in cardiac arrest, increase the current quickly and adjust downward to threshold if capture is obtained. The pacing rate should be selected with a rate high enough for adequate perfusion (common range in adults is 60 to 90 PPM).

Assessing for Capture

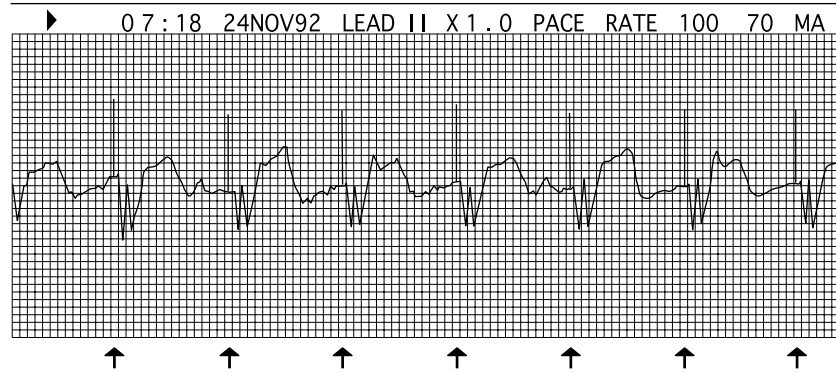
During pacing the patient should be continually monitored by ECG, under constant direct observation, and be frequently assessed for mechanical and electrical capture.

Electrical capture occurs when a pacing stimulus leads to depolarization of the ventricles and is confirmed by ECG changes displayed on the monitor. It is usually represented by a widening of the QRS complex and a tall, broad T wave which is typical of a complex originating in the ventricle. The deflection of the captured complex may be positive or negative. It resembles the ventricular capture seen in permanent or temporary pacing.

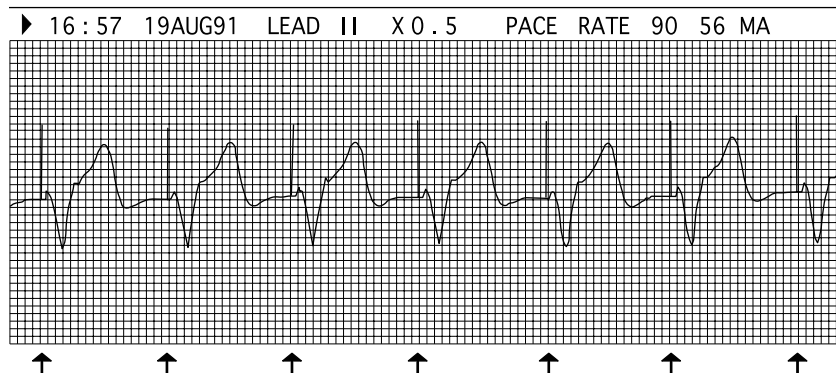
Examples of Electrical Capture



Sensed intrinsic beat (▼) followed by continuous electrical capture.

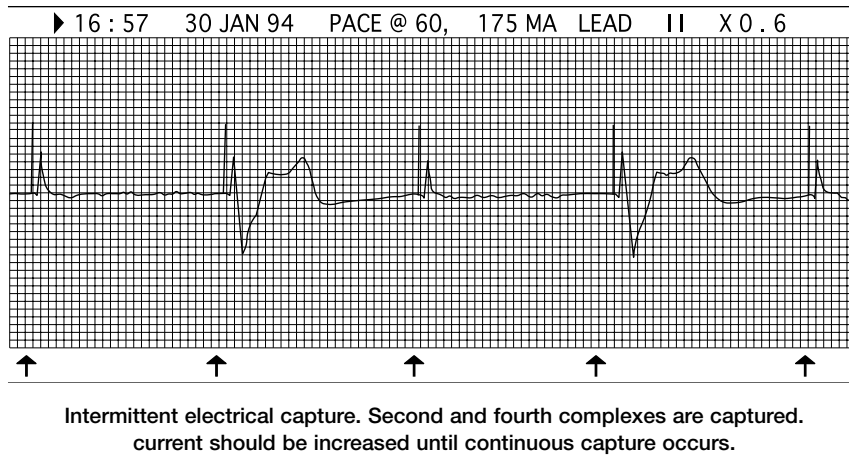
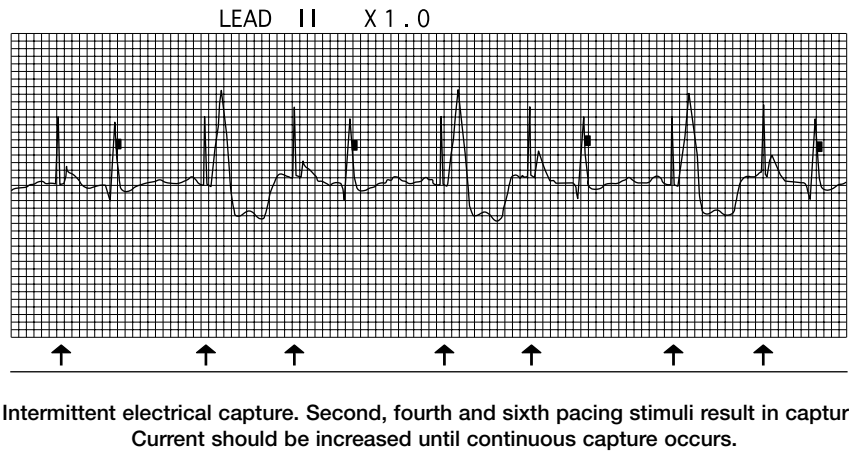
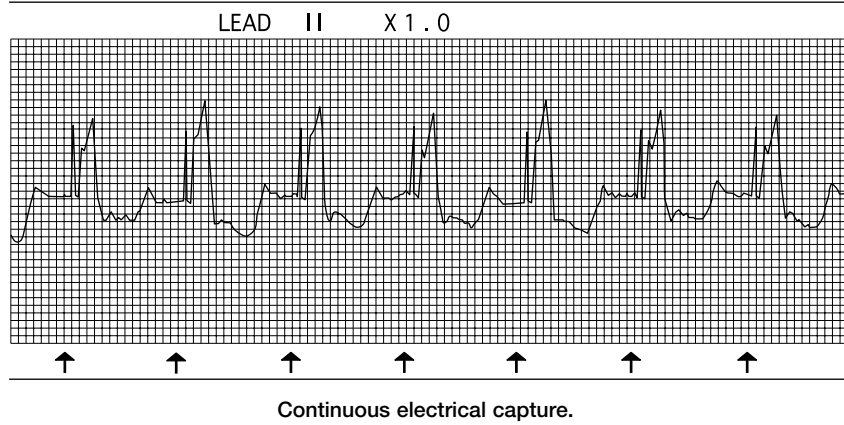


Continuous electrical capture.



Continuous electrical capture.

Examples of Electrical Capture



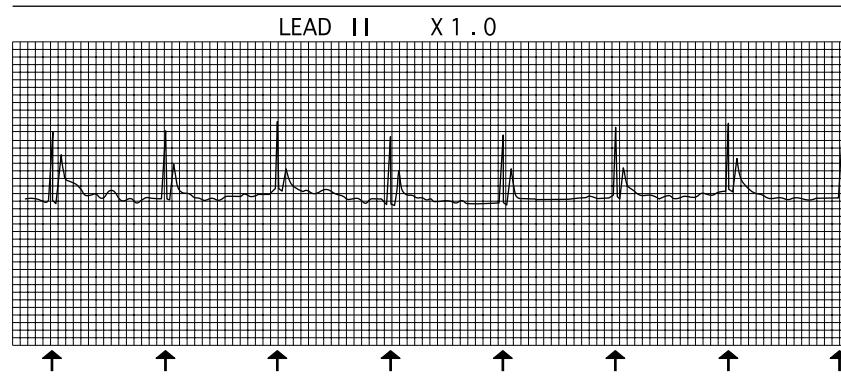
Mechanical capture is the contraction of the myocardium and is evidenced by presence of a pulse and signs of improved cardiac output. Both electrical and mechanical capture must occur to benefit the patient.

Many patients achieve capture at 50 to 100 mA, although individual thresholds vary markedly.^{43,44,45} Recent thoracic surgery, pericardial effusion, pericardial tamponade, hypoxia, acidosis and other physiological variables may lead to higher capture thresholds.⁴⁴ Capture thresholds are not related to body surface area or weight.^{40,44} The most common error in pacing is failure to advance the current high enough to achieve capture. Current must be increased until electrical capture is identified.

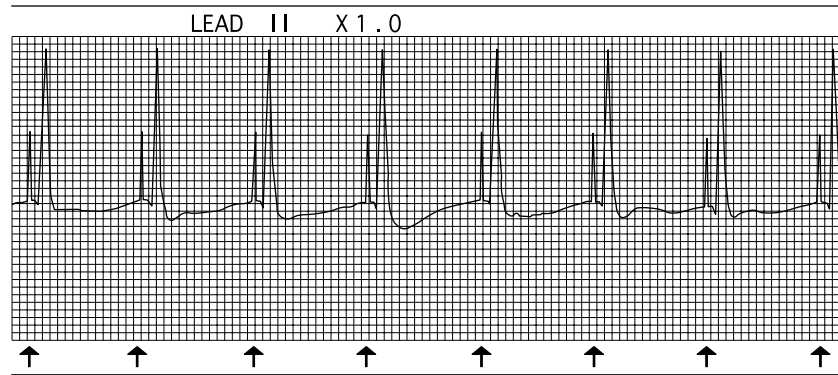
ECG Signal Distortion During Pacing

During routine monitoring the ECG electrodes pick up small electrical signals from the heart which are amplified and displayed on the ECG monitor. During pacing, strong electrical current is transmitted across the chest to the heart. The ECG electrodes normally would pick up the signal caused by this current and display it as artifact on the ECG monitor. In order to minimize this artifact on the ECG display, monitors with integrated noninvasive pacemakers intentionally blank out a brief period of the ECG. The blanked period usually begins when the pace pulse is delivered and lasts 40 to 80 ms, depending on the type of pacemaker. A software generated pace mark is placed on the monitor to signify when the current is being delivered. Although this brief loss of data may not seem ideal, having an interpretable ECG signal is clearly beneficial. Without a blanking period there would be large artifacts and distortion of the ECG signal on the display screen making capture difficult to interpret.

Despite the presence of the blanking period, occasionally some of the ECG artifact may remain and a portion may be seen immediately following the pace pulse. Although the morphology of the artifact is variable, at times it may resemble a QRS complex and is sometimes confused with electrical capture.^{14,45,46} In extreme cases the artifact could mask an underlying rhythm such as ventricular fibrillation.



ECG signal distortion (artifact) following each pace pulse resembling QRS complexes. Sometimes confused with electrical capture.



High amplitude ECG signal distortion (artifact) following each pace pulse resembling QRS complexes. Although sometimes confused with electrical capture, no capture has occurred. Note that artifact returns to the baseline without evidence of a T wave.

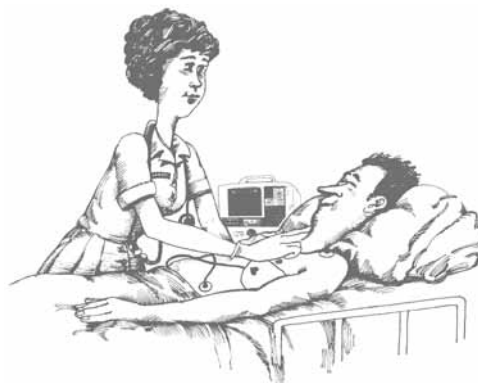It is important to distinguish between electrical capture and artifact during pacing. Artifact will increase in size as current is increased. Positioning the ECG electrodes as far as possible from the pacing electrodes should help to minimize the signal distortion. If ECG signal distortion is severe it may be necessary to select another lead or reposition the ECG electrodes.

Heart rate detectors during noninvasive pacing may not accurately count intrinsic QRS complexes or pacemaker generated complexes. The heart rate detector may incorrectly identify artifact as QRS complexes leading to false high readings. Also, if intrinsic complexes fall within the pacemaker's blanking period they will not be counted by the monitor, leading to false low readings. Thus, display of the actual heart rate during pacing may be inaccurate and should not be considered reliable.

Mechanical Capture

Mechanical capture of the ventricles is evidenced by signs of improved cardiac output, including a palpable pulse, rise in blood pressure, improved level of consciousness, improved skin color and temperature.

Skeletal muscle contractions occur with current delivery and may be evident with energy levels as low as 10 mA. They are not indicative of mechanical or electrical capture and generally become more vigorous as the current is increased. Strong contractions may make it difficult to accurately palpate a pulse. When pacing with the electrodes in the anterior-posterior position, palpation of the carotid, brachial or femoral artery should be done on the patient's right side. Blood pressure should also be measured on this side. Use of a Doppler, capnography and pulse oximetry may also assist in identifying mechanical capture.



Troubleshooting

Common pacing problems such as discomfort, failure to capture, undersensing, oversensing and a noisy ECG signal should be promptly addressed. Effective troubleshooting is important for successful delivery of pacing therapy.

Discomfort

Many patients describe the sensation of pacing as a tingle, twitch, tap or thud, ranging from noticeable to intolerable. A simple explanation of the way in which pacing works and why it is necessary may help the conscious patient and family cope with the procedure. Research indicates that without sedation and analgesia, most subjects have difficulty tolerating pacing when current is above 50 mA.^{7,46} Unfortunately, capture thresholds are generally above this level; therefore, analgesia and sedation should be routinely considered for conscious patients. If using the anterior-posterior pacing electrode placement, moving the anterior electrode toward the midaxillary line (V6) position may reduce discomfort in certain patients.

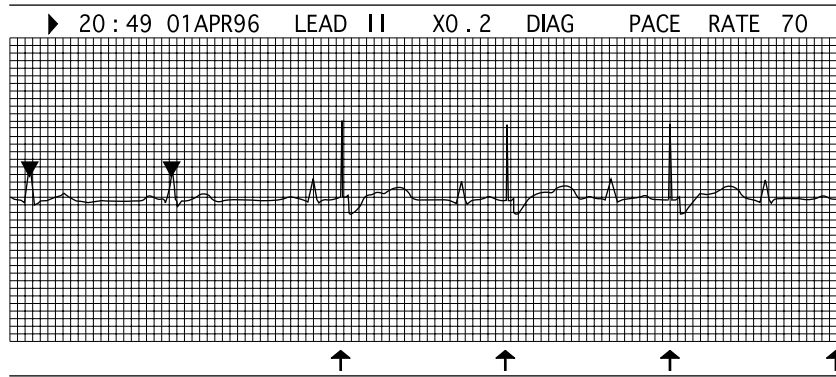
Failure to Capture

The most common reason for not obtaining capture is failure to increase the current sufficiently to electrically stimulate the heart. Capture thresholds vary markedly among individuals and may change over time. Current should be increased as much as needed for electrical capture.

Moving the pacing electrode to another place on the precordium may facilitate capture. Determine if underlying pathophysiology, such as metabolic acidosis or hypoxia, is preventing cardiac response to pacing. The pacemaker, electrodes and cables need to be examined for proper placement and function. Attempting another form of temporary pacing, if available, may be necessary.

Noisy ECG Signal

If the ECG signal is noisy, skin preparation measures may need to be evaluated and corrected. The ECG electrodes may need to be moved farther away from the pacing electrodes, moving the sensitive ECG pick-up away from the source of the current. Finally, selecting another ECG lead may produce a clearer trace. ECG signal noise may also be caused from electromagnetic interference (EMI) which may result from close proximity to equipment such as diathermy, radios or cellular phones. In extreme cases EMI can disable a pacemaker. It is important to keep distance between patients and sources of EMI.

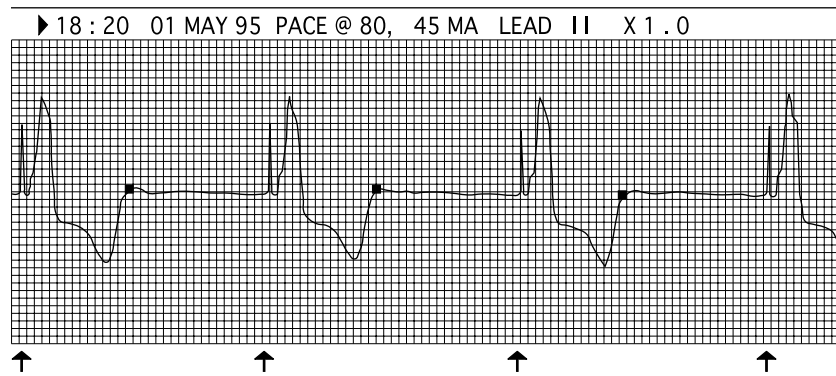


Undersensing: First two QRS complexes are sensed.
Remaining QRS complexes are not of sufficient amplitude to be detected.
Pacemaker fires even though patient's intrinsic rate is above the set pace rate.

Undersensing

Sensing is the ability of the demand pacemaker to identify electrical activity which stems from the myocardium. Undersensing occurs when the pacemaker does not sense intrinsic activity, and delivers a pace pulse (current).

To correct undersensing select a different lead or reposition the ECG electrodes. These troubleshooting measures focus on changing the appearance of the ECG signal to the monitor in order for proper sensing to occur. Skin preparation may need to be repeated and new ECG electrodes applied.



Oversensing: The set rate is 80, but the actual pace rate is 45.
Note sense marker on the T wave which inappropriately inhibits the pacemaker.
Next pace pulse is late which disrupts the timing cycle of the pacemaker.

Oversensing

Oversensing is inappropriate inhibition of a demand pacemaker due to detection of signals other than R waves, such as muscle artifact or T waves. When oversensing occurs the pacemaker will not maintain the set rate. The actual pace rate will lag behind the set pace rate. If oversensing persists, change to a different ECG lead or reposition the ECG electrodes. It may be necessary to select the non-demand pacing mode if all other troubleshooting measures fail.

Safety Precautions

Patients should never be left unattended during noninvasive pacing. Pacing thresholds may change and loss of capture may result. It is safe to touch the patient and perform procedures such as CPR during pacing. If a pacing electrode falls off, therapy will be interrupted. Heart rate alarms, if available, may be unreliable during noninvasive pacing.

CPR may be performed during pacing if certain precautions are observed. The pacing electrodes should be firmly adhered to the chest. Contact with the conductive surface of the electrodes during pacing could result in transmission of pacing current to the operator. Defibrillation gel should be wiped off the chest after defibrillation, and linens should be kept as dry as possible. Gloves should be worn. Following these guidelines, the patient may be touched normally. Occasionally, the operator may experience slight tingling or muscle twitching in the hands. If a strong or painful sensation is felt, pacing and CPR should not be performed simultaneously.

If ventricular fibrillation occurs, the patient should be defibrillated promptly. When defibrillation is needed, defibrillation paddles or defibrillation electrodes should not be placed on the pacing electrodes. Most modern pacemakers are integrated devices with a monitor, defibrillator and pacemaker in one unit. During defibrillation some non-integrated noninvasive pacemakers must be turned off, while others may be left on.

Equipment should be maintained and tested according to manufacturer guidelines. Knowing your equipment is key for successful pacing. Frequent equipment review with hands-on skill drills using a pacing simulator (available from manufacturers) may be helpful in reducing operator errors and improving equipment and operator readiness.



Summary

The typical patient who benefits from noninvasive pacing is one with a primary conduction disturbance or transient disorder such as a post-cardioversion bradycardia or bradycardia secondary to drug toxicity. Early intervention is key.

Pacing is less likely to benefit patients who have been in prolonged cardiac arrest or have extensive myocardial damage or cardiac trauma. Noninvasive pacing will not convert rhythms such as ventricular fibrillation, atrial fibrillation or atrial flutter.

Noninvasive pacing is a valuable therapy in emergency cardiac care. The basic principles of invasive pacing apply to noninvasive pacing. Noninvasive pacing allows rapid initiation of emergency pacing and “buys time” to stabilize the patient and plan further care.



Noninvasive Pacing Procedure

Refer to manufacturer's operating instructions for details.

I. Setup	Key Points
A. Equipment <ul style="list-style-type: none"> • Cardiac monitor, noninvasive pacemaker, defibrillator • ECG electrodes and cable • Pacing electrodes and cable • Advanced cardiac life support supplies 	
B. Patient/family preparation <ul style="list-style-type: none"> • Explain procedure to patient and family 	<ul style="list-style-type: none"> • Skeletal muscle contractions may be vigorous • Sedation and analgesia are available and will be given before and as needed during the procedure
II. Procedure	
A. Connect monitor and acquire baseline rhythm strip	<ul style="list-style-type: none"> • ECG monitoring during demand pacing must be done using ECG electrodes to provide a clear ECG signal • Skin prep for ECG electrodes improves ECG signal quality • Annotated recordings provide useful documentation
B. Obtain vital signs	<ul style="list-style-type: none"> • Serve as a baseline for assessing pacing effectiveness
C. Clip excessive hair on chest under pacing electrodes	<ul style="list-style-type: none"> • Clip rather than shave hair. Nicks in skin may increase discomfort in conscious patient
D. Apply pacing electrodes to clean, dry skin	<ul style="list-style-type: none"> • Anterior-posterior or anterior-lateral placement is equally effective
E. Connect pacing cable to electrodes and to device according to manufacturer's guidelines	
F. Select demand or non-demand pacing mode (if available) <ul style="list-style-type: none"> • Confirm sensing of QRS in demand mode 	<ul style="list-style-type: none"> • Demand mode allows intrinsic complexes to "take over" once the patient's rate exceeds set pace rate • Sensing needs to be assessed prior to and during demand pacing
G. Set current at minimum if not automatically done by pacemaker	
H. Select pace rate	<ul style="list-style-type: none"> • Typical adult pace rates range from 60–90 PPM or high enough for adequate perfusion
I. Activate pacemaker and adjust current upward until electrical and mechanical capture are identified	<ul style="list-style-type: none"> • Current needs to be increased until capture is identified. Typical capture thresholds range between 50–90 mA, but individual thresholds vary markedly. Start slowly in conscious patients. Increase quickly in cardiac arrest patients. • Electrical capture is evidenced by wide QRS and tall broad T wave • Mechanical capture is evidenced by a pulse or signs of improved cardiac output
J. Acquire rhythm strips	<ul style="list-style-type: none"> • Annotated recordings provide useful documentation
K. Assess comfort level	<ul style="list-style-type: none"> • Noninvasive pacing is for short-term use and serves as a bridge therapy until definitive treatment can be implemented
III. Documentation	
A. Date and time pacing initiated B. Rhythm strips prior to and during pacing C. Pacing mode and rate selected D. Current required to capture E. Patient's response to pacing F. Medication used G. Date, time and reason pacing terminated	

Troubleshooting Guideline

The following table may be useful in troubleshooting pacing problems.

Problem	Possible Solution
I. Discomfort during pacing	<ul style="list-style-type: none"> A. Explain procedure to patient; offer reassurance B. Move anterior pacing electrode across the precordium toward the V6 position C. Use sedation and analgesia
II. Failure to capture	<ul style="list-style-type: none"> A. Increase current B. Alter electrode position as above C. Correct metabolic acidosis, hypoxia D. If no skeletal muscle twitching: <ul style="list-style-type: none"> 1. check pacemaker is being used correctly 2. check battery is charged (if not, connect to AC power) E. Consider patient's condition F. Attempt transvenous pacing
III. Electrical capture but no mechanical capture	<ul style="list-style-type: none"> A. Increase current to maximum output; avoid misinterpreting artifact as electrical capture B. Consider cause; patient may not be viable
IV. Undersensing	<ul style="list-style-type: none"> A. Select another ECG lead B. Reposition ECG electrodes C. Repeat skin prep and reapply ECG electrodes
V. Oversensing	<ul style="list-style-type: none"> A. Select another ECG lead B. Reposition ECG electrodes C. Try non-demand mode if available
VI. Noisy ECG signal	<ul style="list-style-type: none"> A. Shave, wash, dry and abrade skin before positioning ECG electrodes B. Use fresh ECG electrodes C. Place ECG electrodes far from the pacing electrodes D. Select another lead E. Move external equipment, which may be source of the noise, away from pacemaker

Nursing Care Plan*

Nursing Diagnosis	Expected Outcome	Nursing Approaches
Alteration in tissue perfusion related to dysrhythmia	Maintenance of vital organ function until definitive treatment is available	Maintain BLS and ACLS to support circulation until external pacing is effective Assess and document pacemaker capture <ul style="list-style-type: none"> • Check ECG for pacer spike followed by wide QRS and tall T wave • Check carotid and femoral pulse for perfusion • Differentiate between muscle artifact, pacing “shock” wave, and pulse Assess vital signs and level of consciousness to determine pacing effectiveness
Alteration in comfort	Increase in comfort level	Set current level at lowest setting that will insure capture Provide analgesics or sedatives as ordered for discomfort caused by skeletal muscle and cutaneous nerve stimulation Position electrodes to provide the lowest pacing threshold
Alteration in gas exchange related to cardiac arrest	Oxygenation of vital organs	Continue respiratory support until spontaneous breathing returns Maintain artificial airways (endotracheal tube, oropharyngeal airway) until ready for intubation Assess and record respiratory status frequently <ul style="list-style-type: none"> • Evaluate arterial blood gas determinations • Assess for bilateral breath sounds • Assess for the return of spontaneous respiration
Anxiety related to knowledge deficit and cardiac emergency	Optimal coping	Support family members during emergency situation Involve patient and family in teaching as patient’s condition permits Explain, in simple terms, external pacemaker’s function Emphasize that situation is temporary and that transvenous pacing may be required Reassure patient and family there is no danger of electrocution Explain to patient that additional medication is available for discomfort Reinforce physician’s explanation of transvenous pacing and prepare patient for insertion (if appropriate) Repeat information and explanations as necessary, since patient and family may have difficulty comprehending information because of high anxiety level

*Nursing Care Plan: Persons CB; Adapted with permission from the C. V. Mosby Company

Frequently Asked Questions

Q: Where do I place the pacing electrodes on a female patient?

A: When using the anterior-posterior placement on female patients, the breast tissue may need to be gently lifted out of the way so the electrode can adhere firmly to the skin directly beneath the breast.

Q: How long can I pace noninvasively?

A: There is no limit to the duration of noninvasive pacing; however, skin condition under the pacing electrodes and patient discomfort need to be monitored carefully during extended pacing. Noninvasive pacing is intended to be a temporary therapy until transvenous pacing can be implemented and typically is not used for more than four to six hours. If invasive pacing is contraindicated, such as in patients with sepsis, noninvasive pacing may be used intermittently for more than 24 hours.

Q: What if no skeletal muscle movement is seen?

A: The response to pacing current varies depending on the electrode placement, body type and the physiological condition of the patient. Factors such as medications and length of time from patient collapse will also alter muscular response to pacing. If no muscle response is observed and accurate pacemaker output has been confirmed by a qualified service technician, other factors should be considered.

Q: During special procedures in which there is limited available space on the chest, can I place pacing electrodes on the patient in the left and right midaxillary lines?

A: Lateral-lateral pacing electrode placement has been used by investigators (midaxillary positions: V6R and V6L); however, capture was rarely obtained.⁴⁸

Q: Can I pace in the rain?

A: Yes, but wipe the chest dry between pacing electrode sites. Rainwater itself is not a good conductor of electricity. However, if defibrillation gel or paste has been used, it can dissolve into the rainwater and improve its conductivity. In a real downpour, it would be safer to gain shelter. Consult the manufacturer for specific information regarding your pacemaker.

Q: I turned the pacing current up until the patient's chest twitched but no capture was observed.

What's wrong?

A: As the pacing current travels from the pacing electrodes through the skin to the heart, it stimulates skeletal muscle on the way. Skeletal muscle twitching does not indicate cardiac capture. Continue to increase pacing current until you see capture on the ECG display; then palpate for a carotid or femoral pulse to confirm mechanical capture.

Q: What about pacing in a helicopter or an airplane?

A: Although pacing is sometimes done in this environment, there could be some electrical interference between sensitive electronic equipment in the aircraft and the pacemaker and monitor. This depends on the type of aircraft, the location and type of equipment on the aircraft, and the pacemaker.

Q: Can I "trim" the adult-sized pacing electrodes for use on pediatric patients?

A: No. Modification of the size or shape of the pacing electrodes can alter current distribution and cause skin burns. Use only commercially available pediatric pacing electrodes. See page 10 for information on pediatric noninvasive pacing.

Q: If a patient is diaphoretic, can I use antiperspirant to prep the skin for pacing electrodes?

A: No. Antiperspirant should not be used to prep the skin before pacing electrode placement. This may result in increased impedance, skin burns and may interfere with proper delivery of therapy.

Q: I was pacing a patient using our noninvasive pacemaker and connected him to our bedside monitor at the same time, but the rhythm on the bedside monitor looked very different from the one on the pacemaker/monitor. Why?

A: The blanking period integral to pacemaker/monitor systems is not present in central monitors so the pacing current will cause ECG distortion (artifact) on the central monitor.

Q: Since I can pace, monitor and defibrillate through multi-function electrodes, do I still need a patient (3-lead cable) when pacing?

A: For demand pacing, the patient cable must always be used. Though multi-function electrodes are capable of performing all three functions separately, prevailing technology does not permit them to pace and monitor simultaneously. The repetitive pacing current, large in comparison to the ECG signal being monitored, will disrupt the ECG display with every pace stimulus delivered. This makes monitoring through the same set of electrodes impossible. For a clearer ECG trace while delivering pacing current, place the ECG electrodes far from the site of the pacing electrodes.

Q: Is there any one noninvasive pacemaker that can pace less painfully than the others?

A: Studies have shown that pacemakers with pulse durations between 20 and 40 milliseconds are similar in effectiveness and patient comfort levels.⁷

References

- McWilliam JA. Electrical stimulation of the heart in man. *Brit Med J*. 1889; 1:348–350.
- Zoll PM. Resuscitation of the heart in ventricular standstill by external electric stimulation. *N Engl J Med*. 1952;247:768–771.
- Zoll PM, Linenthal AJ, Norman LR, et al. Treatment of Stokes-Adams disease by external electric stimulation of the heart. *Circulation*. 1954;9:482–493.
- Zoll PM, Linenthal AJ, Norman LR, et al. External electric stimulation of the heart in cardiac arrest. *Arch Int Med*. 1956;96:639–653.
- Varghese PJ, Bren G, Ross A. Electrophysiology of external pacing: A comparative study with endocardial pacing (abstr). *Circulation*. 1982;66: suppl II:II-349.
- Geddes LA, Babbs CF, Voorhees WD III, et al. Choice of the optimum pulse duration for precordial cardiac pacing: a theoretical study. *PACE*. 1985 8:862–869.
- Falk RH, Battinelli NJ. External cardiac pacing using low impedance electrodes suitable for defibrillation: a comparative blinded study. *J Am Coll Cardiol*. 1993;8:1354–1358.
- Chardack WM, Gage AA, Greatbatch W. A transistorized, self-contained, implantable pacemaker for the long-term correction of complete heart block. *Surgery*. 1960; 48:643–653.
- Medei M, Brinker J. Pacemaker Implantation. In: Ellenbogen KA, ed. *Cardiac Pacing*. Boston, Ma: *Blackwell Scientific Publications*; 1992:211–261.
- Furman S, Escher DJW, Parker B. Results of long-term pacemaker implantation. In: Dreifus L, Likoff W (eds): *Cardiac Arrhythmias*. New York, NY: Grune and Stratton, 1973:599–605.
- Silver MD, Goldschlager N. Temporary transvenous cardiac pacing in the critical care setting. *Chest*. 1988;93:607–613.
- Wood M, Ellenbogen K, Haines D. Temporary cardiac pacing. In: Ellenbogen KA, ed. *Cardiac Pacing*. Boston, Ma: *Blackwell Scientific Publications*; 1992:162–210.
- Austin JL, Preis LK, Crampton RS, et al. Analysis of pacemaker malfunction and complications of temporary pacing in the coronary care unit. *Amer J Cardiol*. 1982;49:301–306.
- Dunn DL, and Gregory JJ. Noninvasive temporary pacing: experience in a community hospital. *Heart and Lung*. 1989;18:23–28.
- Johnson LG, Brown OF, Allgood MR. Complications of epicardial pacing wire removal. *J Cardiovasc Nurs*. 1993;7:32–40.
- Millikan JS, Moore EE, Dunn EL. Temporary cardiac pacing in traumatic cardiac arrest victims. *Ann of Emerg Med*. 1980;9:591–593.
- Brown CG, Gurley HT, Hutchins GM. Injuries associated with percutaneous placement of transthoracic pacemakers. *Annals of Emerg Med*. 1985; 14:223–228.
- Niemann JT, Rosborough JP, Garner D. External noninvasive cardiac pacing: A comparative hemodynamic study of two techniques with conventional endocardial pacing. *PACE*. 1984;7:230–236.
- Syverud SA, Hedges JR, Dalsey WC. Hemodynamics of transcutaneous cardiac pacing. *Amer J Emerg Med*. 1986;4:17–20.
- Feldman MD, Zoll PM, Aroesty JM. Hemodynamic responses to noninvasive external cardiac pacing. *Amer J Med*. 1988;84:395–400.
- Falk RH, Ngai STA, Kumaki DJ, et al. Cardiac activation during external cardiac pacing. *PACE*. 1987;10:503–506.
- Talit U, Leach CN, Werner MS, et al. The effect of external cardiac pacing on stroke volume. *PACE*. 1990;13:598–602.
- Syverud SA, Dalsey WC, Hedges JR, et al. Transcutaneous cardiac pacing: Determination of myocardial injury in a canine model. *Ann Emerg Med*. 1983; 12:745–748.
- Kicklighter EJ, Syverud SA, Dalsey WC, et al. Pathological aspects of transcutaneous cardiac pacing. *Amer J Emerg Med*. 1985;3:108–113.
- Madsen JK, Flemming P, Grande P. Normal myocardial enzymes and normal echocardiographic findings during transcutaneous pacing. *PACE*. 1988; 11:1188–1193.
- O'Toole KS, Paris PP, Heller MB, et al. Emergency transcutaneous pacing in the management of patients with bradyasystolic rhythms. *J Emerg Med*. 1987; 5:267–273.
- 2005 American Heart Association Guidelines for Cardiopulmonary Resuscitation and Emergency Cardiac Care. *Circulation*. 2005;112 (Suppl IV).
- Barthell E, Troiano P, Olson D, et al. Prehospital external cardiac pacing: a prospective, controlled clinical trial. *Ann Emerg Med*. 1988;17:1221–1226.
- Hedges JR, Feero S, Schultz B, et al. Prehospital transcutaneous cardiac pacing for symptomatic bradycardia. *PACE*. 1991;14:1473–1478.
- Syverud SA, Dalsey WC, Hedges JR. Transcutaneous and transvenous cardiac pacing for early bradyasystolic cardiac arrest. *Ann Emerg Med*. 1986;15:121–124.
- Cummins RO, Graves JR, Larsen MP, et al. Out-of-hospital transcutaneous pacing by emergency medical technicians in patients with asystolic cardiac arrest. *N Engl J Med*. 1993;328:1377–1382.
- Tachakra SS, Jepson E, Beckett MW. Successful transcutaneous external pacing for asystole following cardiac arrest. *Arch Emerg Med*. 1988;5:184–185.
- Eitel DR, Guzzardi LJ, Stein SE. Noninvasive transcutaneous cardiac pacing in prehospital cardiac arrest. *Ann Emerg Med*. 1987;16:531–534.
- Luck JC, Grubb BP, Artman SE, et al. Termination of sustained ventricular tachycardia by external noninvasive pacing. *Am J Cardiol*. 1988;61:574–577.
- Grubb BP, Temesy-Armos P, Hahn H, et al. The clinical use of external noninvasive pacing in the termination of sustained ventricular tachycardia. *PACE*. 1990; 13:1092–1095.
- Grubb BP, Samoil D, Temesy-Armos P, et al. The use of external noninvasive pacing for the termination of supraventricular tachycardia in the emergency department setting. *Ann Emerg Med*. 1993;22:714–717.
- Cardiac rhythm disturbances. In: Chameides L, Hazinski MF, (eds): *Pediatric Advanced Life Support*. Dallas, Texas: American Heart Association. 1994 ;7–1–7–11.
- Cummins RO, Haulman J, Quan L, et al. Near fatal yew berry intoxication treated with external cardiac pacing and digoxin-specific FAB antibody fragments. *Ann Emerg Med*. 1990;19:38–43.
- Beland MJ. Noninvasive transcutaneous cardiac pacing in children. In: Birkui P, Trigano J, Zoll P (eds): *Noninvasive transcutaneous cardiac pacing*. Mount Kisco, N.Y: *Futura Publishing Company, Inc*, 1993;91–98.
- Beland MJ, Hesslein PS, Finlay CD, et al. Noninvasive transcutaneous cardiac pacing in children. *PACE*. 1987;10:1262–1270.
- Voorhees WD, Foster KS, Geddes LA, et al. Safety factor for precordial pacing: minimum current thresholds for pacing and for ventricular fibrillation by vulnerable-period stimulation. *PACE*. 1984;7:356–360.
- Falk RH, Ngai STA. External cardiac pacing: Influence of electrode placement and pacing threshold. *Crit Care Med*. 1986;14:931–932.
- Madsen JK, Meibom J, Videbak R. Transcutaneous pacing: Experience with the ZOLL noninvasive temporary pacemaker. *Am Heart J*. 1988;116:7–10.
- Kelly JS, Royster RR, Angert KC, et al. Efficacy of noninvasive transcutaneous cardiac pacing in patients undergoing cardiac surgery. *Anesthesiology*. 1989; 70:747–751.
- Sharkey SW, Chaffee V, Kapsner S. Prophylactic external pacing during cardioversion of atrial tachyarrhythmias. *Am J Cardiol*. 1985;1632–1634.
- Knowlton AA, Falk RH. External cardiac pacing during in-hospital cardiac arrest. *Am J Cardiol*. 1986;57:1295–1298.
- Persons CB. External cardiac pacing in the emergency department. *J Emerg Nurs*. 1986;12:348–352.
- Kennitz J, Winter J, Vester EG., et al. Transcutaneous cardiac pacing in patients with automatic implantable cardioverter defibrillators and epicardial patch electrodes. *Anesthesiology*. 1992;77:258–262.

Glossary

artifact

- 1) A waveform made by a stylus on an ECG strip.
- 2) In pacing, usually refers to pace marker or "spike."
- 3) An extraneous signal, such as from skeletal muscle contractions or after current delivery during noninvasive pacing. Sometimes referred to as afterpotential or signal distortion.

artificial pacemaker

An electronic instrument used to artificially stimulate the heart; a pacemaker is a combination of pulse generator and cable or lead-wire and electrodes.

asystole

Condition in which the heart does not contract and there is no electrical activity; cardiac standstill. Seen on the ECG as a straight line.

atrioventricular (AV) node

Small bundle of specialized conductive cells which transmit electrical impulses from the atria to the ventricles.

AV synchrony

The coordinated timing of atrial and ventricular contractions to provide emptying of the atrial contents into the ventricles during the last half of ventricular filling.

automaticity

The inherent property of individual myocardial cells to generate an electrical impulse.

blanking period

Brief period (approx. 40 to 80 ms) on the monitor screen and the ECG recording strip in which data is blanked in order to minimize artifact.

bradycardia or bradyarrhythmia

Low heart rate usually defined as below 60 bpm.

bundle branch

Either of two branches just below the bundle of His; the bundle branches descend through the interventricular septum into the ventricles.

bundle of His

Bundle of conduction fibers which descend from the AV node to the interventricular septum, before splitting into the bundle branches.

capture

Depolarization of the heart by an artificial electrical stimulus. Electrical capture is evidenced by a wide QRS complex followed by a tall, broad T wave. Mechanical capture is myocardial contraction and is evidenced by a pulse and signs of improved cardiac output.

cardiac arrest

Cessation of ventricular activity; lack of heartbeat or peripheral pulse.

cardiac output

Volume of blood pumped by the heart per minute.

cardiac tamponade

Compression of venous return to the heart due to excess fluid in the pericardium.

cardioversion

1) Most commonly used to describe termination of certain dysrhythmias by an electrical stimulus which is synchronized to the QRS complexes. 2) Broadly used to describe termination of ventricular fibrillation by an asynchronous, high energy, electrical stimulus.

CKMB

An enzyme found in myocardial cells; when the cells are injured, as in a myocardial infarction, CKMB is released into the bloodstream where it can be measured as an indicator of myocardial injury.

complete heart block

See "heart block."

conduction

The transmission of an electrical impulse. In electrophysiology, the term refers to the active propagation of a wave of depolarization in the heart.

defibrillation

Termination of ventricular fibrillation by an asynchronous, high energy, electrical stimulus.

demand pacemaker

Pacemaker capable of sensing spontaneous cardiac activity so that pacemaker stimuli are delivered only when necessary.

depolarization

In excitable muscle or nerve tissues, the sudden change in electrical potential from negative to slightly positive. In the heart, depolarization usually results in a contraction.

dysrhythmia

Abnormal rhythm of the heart. The rate, regularity or propagation sequence of depolarization may be abnormal.

electrocardiogram (ECG or EKG)

Graphic representation of the heart's electrical activity as detected by skin (external) or internal electrodes.

electrode

Electrically conductive element which contacts body tissue.

epicardial wires

Temporary wires which are loosely sutured to the outermost layer of the heart and then exposed through the skin and connected to a pulse generator for temporary pacing.

escape interval

Time between the sensing of a spontaneous beat and the subsequent pacing stimulus of the pulse generator.

external pacemaker

1) Non-implantable artificial pacemaker used outside the body and applied to temporary pacing wires to stimulate the heart. 2) Noninvasive artificial pacemaker used outside the body using self-adhesive skin electrodes to stimulate the heart.

fibrillation (ventricular)

Chaotic, high-rate unsynchronized quivering of the myocardium, resulting in ineffectual cardiac pumping.

first degree heart block

See "heart block."

fluoroscopy

Examination of an internal structure by a continuous viewing of shadows formed by differential transmission of X-rays through the objects.

heart block

Defect in the conduction of impulses from the atria to the ventricles.

– first degree heart block

Prolonged interval (greater than 200 ms) between atrial and ventricular depolarizations. Seen as a prolonged PR interval on the ECG.

– second degree block

Blockage of some, but not all, impulses traveling from the atria to the ventricles. There are two types: Mobitz I, also known as the Wenckebach phenomenon, is the progressive prolongation of the PR interval, until one P wave is not followed by a QRS. Mobitz II is the occasional loss of a QRS without any prolongation of the PR interval.

– complete heart block

A condition in which all impulses from the atria are blocked. In this condition, an ectopic focus in the AV node or ventricles usually takes over.

hypoxia

Oxygen deficiency in body tissues.

idioventricular rhythm

Rhythm arising from a ventricular focus.

impedance

The total opposition to the flow of current in an electrical component or circuit, including all effects (resistance, capacitance, and inductance).

impulse

The output pulse of a pulse generator.

infarction

Area of tissue which is deprived of its blood supply and is damaged.

inherent rate

The rate of impulse formation in various areas of the conduction system: SA node—60 to 100/minute, AV node—40 to 60/minute, ventricle—20 to 40/minute

intrinsic

Inherent; originating from the organ itself. For example, an intrinsic beat refers to a naturally occurring heart beat.

ischemic tissue

Tissue which has inadequate blood supply to maintain normal function.

junctional rhythm

Sometimes called AV nodal rhythm; cardiac rhythm originating in the AV node; rate usually 40 to 60 beats per minute.

milliamps (mA)

One-thousandth of an ampere. An ampere (amp or A) is a unit of measure of electrical current.

millisecond (ms)

One-thousandth of a second.

myocardium

The muscular heart wall, lying between the inner (endocardial) and outer (epicardial) layers of the heart.

non-demand pacemaker

Pacemaker which delivers pacing stimuli at a set rate independent of the heart's electrical or mechanical activity; contains no mechanism capable of sensing cardiac activity. May be referred to as fixed rate or asynchronous pacemaker.

output pulse

The electrical pulse used to stimulate the heart, measured in voltage, current, or energy, and applied for a known pulse duration.

overdrive pacing

Pacing the heart at a rate faster than the patient's intrinsic rate to terminate a tachyarrhythmia or to suppress premature ventricular contractions (PVC's).

oversensing

Inhibition of a pacemaker due to sensing of signals other than R waves, such as muscle artifact, or P or T waves.

pace interval

The time between pace pulses, usually measured in milliseconds.

percutaneous

Introduced through the skin; regarding pacing, the introduction of an endocardial lead through a small puncture in the skin and into a vein.

PR interval

Extends from beginning of P wave to onset of Q wave and is representative of the conduction time between atria and ventricles.

pulse generator

The part of the pacemaker which contains the power source and circuitry.

pulse width

In a demand pacemaker, the duration of the electrical impulse which is delivered to the heart, expressed in milliseconds. Also called pulse duration.

pulses per minute (PPM)

A pacemaker's rate of stimulus delivery, sometimes called beats per minute (bpm).

Purkinje fibers

Network of ventricular muscle fibers which comprise the ventricular conduction system.

P wave

A deflection present on ECG which represents the depolarization of the atria.

QRS complex

Commonly referred to as an R wave; the portion of the ECG produced by ventricular depolarization.

refractory period

1) In a demand pacemaker, the length of time following a pace impulse during which the pacemaker is incapable of sensing cardiac activity. 2) In the heart, the length of time after depolarization that the heart is incapable of another depolarization.

repolarization

Electrical recovery of the heart; repolarization of the ventricles is seen as the T wave on the ECG.

R wave

See “QRS complex.”

second degree heart block

See “heart block.”

sense mark

Mark on the QRS complex made by some noninvasive pacemakers.

sick sinus syndrome

Broad term describing a variety of SA node abnormalities resulting in slow or irregular heart rates.

sino-atrial (SA) node

A small bundle of specialized conductive cells located high in the right atrium which initiates an electrical impulse 60–100 times per minute; the heart’s natural pacemaker.

spike

On an ECG recording, the artifact of an electronic pacemaker’s impulse.

stimulation threshold

Minimum level of energy, voltage or current needed to consistently depolarize the heart (also known as energy threshold, voltage threshold, current threshold, capture threshold).

Stokes-Adams disease or syndrome

Set of symptoms (including light-headedness, fainting, etc.) due to complete heart block.

supraventricular tachycardia

A tachycardia originating in any part of the atrium, the AV node, or the bundle of His.

syncope

A brief period of unconsciousness caused by an insufficient supply of blood to the brain.

T wave

Deflection on the ECG which represents electrical recovery (repolarization) of the ventricles.

tachycardia

Rapid heart rate usually defined as greater than 100 BPM

thoracotomy

Incision into the chest wall.

thrombolytics

Agents which activate plasminogen to form plasmin. Plasmin digests fibrin and dissolves clots.

undersensing

Failure to sense the intrinsic QRS complex causing the pulse generator to deliver impulses inappropriately.

ventricular inhibited (VVI)

Term used for a demand pacemaker in which a pulse generator detects spontaneous ventricular depolarizations and suppresses its output upon detection or stimulates the ventricle if no spontaneous cardiac activity occurs upon expiration of the preset interval.

vulnerable period

A period represented by the T wave during which a stimulus could cause ventricular fibrillation, particularly in a diseased heart.

waveform

Shape or morphology of an electronic pulse over time as viewed on an oscilloscope.

EDUCATIONAL SERIES

Noninvasive Pacing

What You Should Know



HEADQUARTERS / MANUFACTURING

Physio-Control, Inc.
11811 Willows Road NE
Redmond, WA 98052 USA
Tel. 425 867 4000
Toll Free. 800 442 1142
www.physio-control.com

SALES OFFICES

Physio-Control UK
Medtronic Ltd
Suite One, Sherbourne House
Croxley Business Park
Watford, Herts
WD18 8WW
Tel. 44 1923 212 213

Canada
Medtronic of Canada
6733 Kitimat Road
Mississauga, ON
L5N 1W3
Tel. 888 879 0977